UNCLASSIFIED

AD NUMBER

AD868356

NEW LIMITATION CHANGE

TO

Approved for public release, distribution unlimited

FROM

Distribution authorized to U.S. Gov't. agencies and their contractors; Foreign Government Information; APR 1970. Other requests shall be referred to Department of the Army, Fort Detrick, Attn: Technical Release Branch/TID, Frederick, MD 21701.

AUTHORITY

BDRL ltr, 29 Sep 1971

THIS PAGE IS UNCLASSIFIED

Best Available Copy

AD

TECHNICAL MANUSCRIPT 600

PULMONARY ALVEOLAR EPITHELIAL CHANGES IN RESPONSE TO FREUND'S ADJUVANT

Charles S. Faulkner II

John R. Esterly

APRIL 1970

STATEMENT #2 UNCLASSIFIED
This document is subject to special export controls and each transmittal to foreign governments or foreign nationals may be made only with prior approval of Dept. of Army, Fort Detrick, ATTN: Technical Release Branch/TID, Frederick, Maryland 21701

DEPARTMENT OF THE ARMY
Fort Detrick
Frederick, Maryland

Reproduced by the
CLEARINGHOUSE
for Federal Scientific & Technical
Information Springfield Va. 22151

DDC
RECEIVED
MAY 4 1970
C

Best Available Copy

Reproduction of this publication in whole or in part is prohibited except with permission of the Commanding Officer, Fort Detrick, ATTN: Technical Release Branch, Technical Information Division, Fort Detrick, Frederick, Maryland, 21701. However, DDC is authorized to reproduce the publication for United States Government purposes.

DDC AVAILABILITY NOTICES

Qualified requesters may obtain copies of this publication from DDC.

Foreign announcement and dissemination of this publication by DDC is not authorized.

Release or announcement to the public is not authorized.

DISPOSITION INSTRUCTIONS

Destroy this publication when it is no longer needed. Do not return it to the originator.

The findings in this publication are not to be construed as an official Department of the Army position, unless so designated by other authorized documents.

DEPARTMENT OF THE ARMY
Fort Detrick
Frederick, Maryland 21701

TECHNICAL MANUSCRIPT 600

PULMONARY ALVEOLAR EPITHELIAL CHANGES IN RESPONSE TO FREUND'S ADJUVANT

Charles S. Faulkner II

John R. Esterly

Pathology Division
MEDICAL SCIENCES LABORATORIES

Project 1T061101A91A

April 1970

In conducting the research described in this report, the investigators adhered to the "Guide for Laboratory Animal Facilities and Care," as promulgated by the Committee on the Guide for Laboratory Animal Facilities and Care of the Institute of Laboratory Animal Resources, National Academy of Sciences-National Research Council.

PULMONARY ALVEOLAR EPITHELIAL CHANGES IN RESPONSE TO FREUND'S ADJUVANT*

ABSTRACT

Observation of lungs of rabbits 3 weeks after intravenous injection of complete Freund's adjuvant indicates that both alveolar cell types (granular pneumonocytes and membranous pneumonocytes) participate in the reaction of the lung to the adjuvant. Our findings also suggest that these two cell types have a common origin and/or that transformation from one cell type to the other may occur.

After the epithelial cells that line the pulmonary alveoli had been described in the literature, a considerable body of information was published concerning the normal appearance and function of these cells and their roles in certain experimental processes. It is only much more recently, however, that these cells have been observed to participate in the reaction of the pulmonary parenchyma to various forms of injury. There are now increasing numbers of observations of ultrastructural abnormalities in these cells. This report describes our experience with the reaction of pulmonary alveolar epithelial cells to the intravenous injection of complete Freund's adjuvant.

The morphologic features of the pulmonary reaction to this stimulus have been studied by several groups of investigators.[1-6] Almost without exception, however, the primary focus of attention has been the mononuclear cell response. Indeed, this sort of technique is commonly used to provide abundant harvests of mononuclear cells for in vitro studies.[7] The fact that identifiable alveolar epithelial cells do not usually appear in lung washings has not received much comment, partly because it is only relatively recently that we have been able to distinguish with some certainty between the granular pneumonocyte and the alveolar macrophage or phagocyte pneumonocyte.

Adult New Zealand rabbits received 1 ml of complete Freund's adjuvant via the marginal ear vein. They were sacrificed at intervals of 3 to 4 weeks. This time was chosen because it is the time of the peak cellular response in the lung, as observed histologically and by lung washings.

---

* This report should not be used as a literature citation in material to be published in the open literature. Readers interested in referencing the information contained herein should contact the senior author to ascertain when and where it may appear in citable form.

Small fragments of the lungs were fixed in phosphate-buffered 2.5% glutaraldehyde. The specimens were subsequently osmicated, dehydrated, and embedded in epoxy resin according to the technique of Luft.[8] Thin sections for electron microscopy were stained with uranyl acetate and lead citrate. Similarly processed tissues from uninjected animals served for comparison.

In the normal (control) animals the granular pneumonocytes and the membranous pneumonocytes had the morphologic features characteristic of these cell types (Fig. 1). The granular pneumonocytes were round or oval cells, situated either in corners of alveoli or on more flattened surfaces of alveolar walls, applied directly to the alveolar basement membrane. They each had a single somewhat basally located nucleus and numerous typical lamellated inclusions, usually near the luminal surface. The adjacent membranous pneumonocytes usually extended up to cover the sides of the granular pneumonocytes, with a desmosome near the top of the interface between the two cells. Varying numbers of regular, small microvilli were present on the free borders of the granular pneumonocytes. The membranous pneumonocytes were thin, attenuated cells with relatively smooth surfaces. They contained a few mitochondria and ribosomes, with little other evidence of differentiation.

In the animals that received complete Freund's adjuvant, the expected striking infiltrate of large mononuclear cells was present. Additional comments on this process are presented below. More pertinent to the interests of this investigation were the changes in the epithelial cells. These alterations were present chiefly in the areas where the mononuclear cell accumulations were found, but were also seen in the areas where the pulmonary parenchyma appeared more nearly normal.

The most prominent of these changes occurred in the granular pneumonocytes. These cells were present in greater numbers than in the normal control lungs. It was not uncommon to find three granular pneumonocytes within one cell diameter of one another, a situation that we have not observed in normal rabbit lungs. Although we found no mitotic figures in our material, we observed a number of granular pneumonocytes with two closely adjacent nuclei (Fig. 2). In other instances, two granular pneumonocytes were immediately adjacent to one another, with desmosomes near the alveolar surfaces and with complex, interdigitating cell membranes (Fig. 3). Neither the binucleate granular pneumonocytes nor adjacent ones were seen in the control material.

Alterations of cytoplasmic structures were present in many of the granular pneumonocytes. The most prominent of these involved the lamellar inclusions. These bodies were frequently several times larger than normal and contained relatively large amounts of very electron-dense, lamellated material (Fig. 3 and 4). No attempt was made to quantitate the number of inclusions, but the appearance suggested that the apparent increase was only in size of the bodies, not in numbers.

FIGURE 1. Granular and Membranous Pneumonocytes from Normal Rabbit.

FIGURE 7. Binucleate Gram[illegible] [illegible]mononocyte in Lung from Rabbit Stimulated with Cresol[illegible] F[illegible] [illegible] Adjuvant.

FIGURE 3. Closely Adjacent Granular Pneumonocytes from Rabbit Stimulated with Complete Freund's Adjuvant.

FIGURE 4. Prominent Lamellar Inclusions in Granular Pneumonocyte from Rabbit Stimulated with Complete Freund's Adjuvant.

In addition, the granular pneumonocytes presented a variety of configurations other than the usual round shape. Many were somewhat flattened (Fig. 5), and some of these flattened cells were completely covered by the thin cytoplasm of a membranous pneumonocyte (Fig. 6). Often, when the free surface of the granular pneumonocyte was not covered, the usual microvilli were absent or reduced in size and number. Many of these cells contained prominent, dilated, rough endoplasmic reticulum. The mitochondria of some of these cells were also altered, occasionally with small myelin figures located in the center (Fig. 7 and 8).

The membranous pneumonocytes also appeared to have participated in the reaction. Frequently, their alveolar surfaces were marked by considerably more irregularity than the normal relatively smooth surface (Fig. 9). Often these cells extended to cover much more than the normal amount of the surface of the granular pneumonocyte, as mentioned above. In many areas the thickness of the membranous pneumonocyte appeared greater than normal, and occasionally these thickened areas contained a lamellated inclusion closely resembling those of the granular pneumonocytes (Fig. 9).

The appearance of the accumulations of mononuclear cells, or granulomata, was quite consistent with the description published by Galindo and Imaeda.[8] The mononuclear cells were closely adjacent to one another, often with remarkable interdigitating membranes. Their cytoplasmic structures varied in relative numbers from one cell to another (Fig. 10).

An interesting feature of these granulomata was their location in relation to the pulmonary parenchyma. This could not be ascertained clearly in the light microscope, and the granulomata have often been assumed to be interstitial. Careful study of adjacent electron micrographs of large areas of tissue revealed that many of these closely packed accumulations of cells are actually situated within airspaces, clearly separate from the intact alveolar surface (Fig. 11-13). The only apparent difference between interstitial and intra-alveolar granulomata was that only the former contained plasma cells.

Another interesting observation was the number of immature-appearing mononuclear cells seen in the blood vessels throughout the lungs. This and the presence of similar young mononuclear cells in the granulomata correlate very well with the current evidence that a major portion of the mononuclear phagocyte population of the lung comes from the bone marrow via the bloodstream.[9,10]

The definitive description of the epithelium that lines the alveoli was published by Low in 1953.[11] Subsequent work by Schaefer et al.[12] established that the granular pneumonocytes responded to CO_2 excess chiefly by alterations in the content of the lamellar bodies. Similar changes occur in the granular pneumonocytes of immature lambs with experimental respiratory distress.[13] Goldenberg et al.[14] have recently described the

FIGURE 5. Flattened Granular Pneumonocyte from Rabbit Stimulated with Complete Freund's Adjuvant.

FIGURE 6. Membranous Pneumonocyte Covering Flattened Granular Pneumonocyte from Rabbit Stimulated with Complete Freund's Adjuvant.



FIGURE 7. Granular Pneumonocyte with Dilated Rough Endoplasmic Reticulum and Altered Mitochondria from Rabbit Stimulated with Complete Freund's Adjuvant.

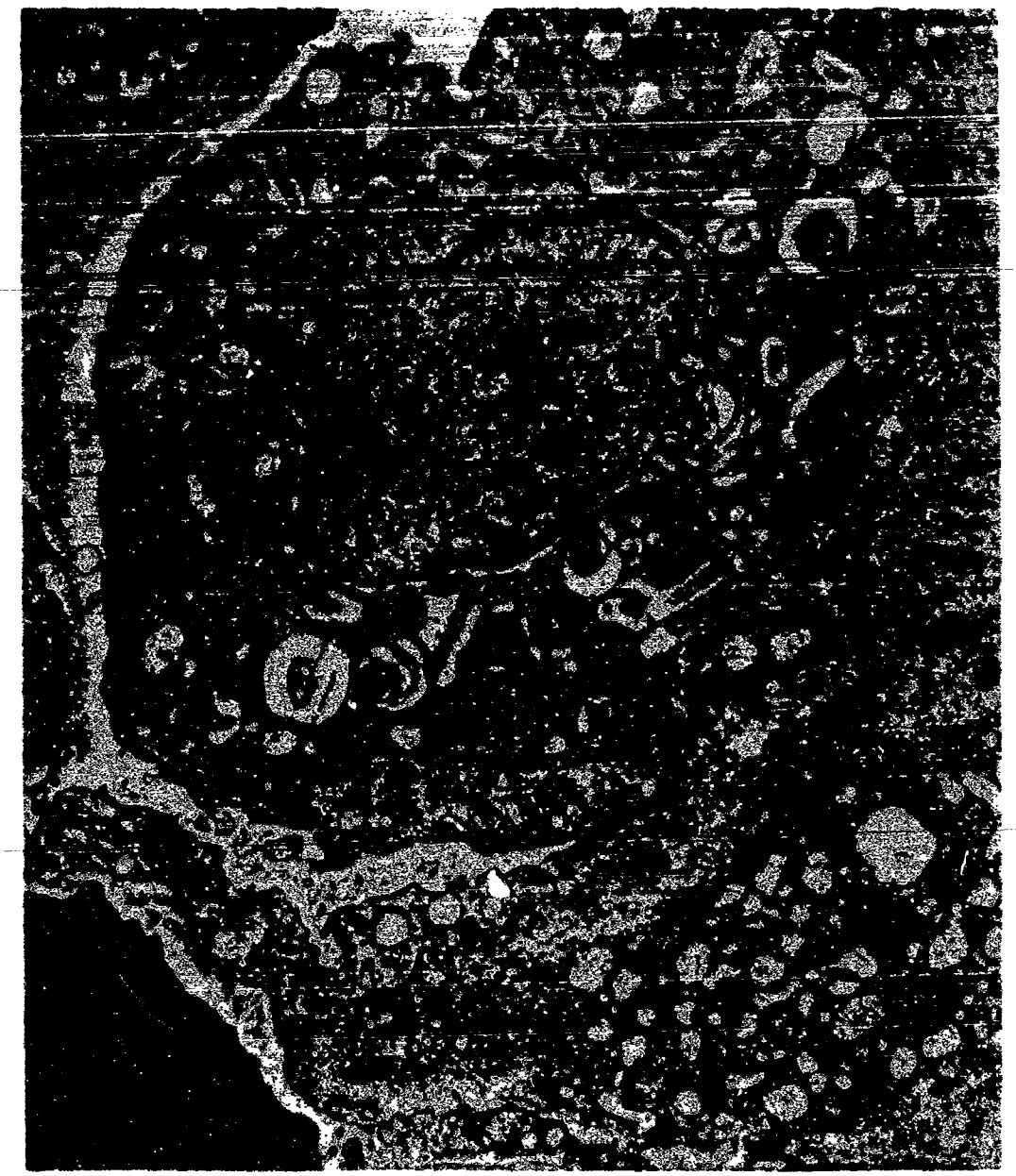

FIGURE 8. Granular Pneumonocyte with Dilated Rough Endoplasmic Reticulum and Altered Mitochondria from Rabbit Stimulated with Complete Freund's Adjuvant.

FIGURE 9. Irregular Surface of Membranous Pneumonocyte from Rabbit Stimulated with Complete Freund's Adjuvant.

FIGURE 10. Mononuclear Cells in Granuloma from Rabbit Stimulated by Complete Freund's Adjuvant.



FIGURE 11. Intra-Alveolar Granuloma from Rabbit Stimulated with Complete Freund's Adjuvant.



FIGURE 12. Interstitial Granuloma from Rabbit Stimulated with Complete Freund's Adjuvant.

FIGURE 15. Intravascular (left) and Intra-Alveolar (right) Granulomata Induced by Inoculation of Complete Freund's Adjuvant.

responses of the granular pneumonocytes to pilocarpine stimulation, consisting of an enhancement of the production and secretion of the contents of the lamellar bodies. Oxygen poisoning causes changes in the mitochondria and endoplasmic reticulum of the granular pneumonocytes of rats.[16] Granular pneumonocytes also undergo alterations in the course of proliferative reactions. In pulmonary adenomata of mice,[16-18] desquamative interstitial pneumonia,[19] and pulmonary alveolar proteinosis,[20] these cells are found in much greater numbers than normal. The shape of the cells is often somewhat altered, and there are frequent lamellar inclusions that differ from the normal, although the large forms seen in our material have not been mentioned in the literature. In these descriptions there has also been no mention of the membranous pneumonocytes, whether normal or altered.

The first published observations of major alterations in the granular pneumonocytes were those of Hackett and Sunderman.[21] They injected nickel carbonyl in the tail vein of rats, and over a period of as long as 8 days found changes strikingly similar to those observed in our studies. They particularly emphasized their findings of enlargement of the membranous pneumonocytes and remarkable increase in cytoplasmic organelles of these cells. They felt that these alterations suggested that membranous pneumonocytes might be undergoing transformation into granular pneumonocytes. Our observations are quite consistent with this suggestion, although we have not obtained definitive evidence of such a transformation.

This striking similarity between the changes seen in response to two stimuli as different as nickel carbonyl and complete Freund's adjuvant suggests that this reaction may be quite nonspecific. This in turn would suggest that further investigation in the electron microscope of other forms of lung injury would lead to similar findings.

LITERATURE CITED

1. Laufer, A.; Tal, C.; Behar, A.J. 1959. Effect of adjuvant (Freund's type) and its components on the organs of various animal species: A comparative study. Brit. J. Exp. Pathol. 40:1-7.

2. Steiner, J.W.; Langer, B.; Schatz, D.L. 1960. The local and systemic effects of Freund's adjuvant and its fractions. Arch. Pathol. 70:424-430.

3. Youmans, G.P.; Youmans, A.S. 1964. An acute pulmonary granulomatous response in mice produced by mycobacterial cells and its relation to increased resistance and increased susceptibility to experimental tuberculous infection. J. Infect. Dis. 114:135-151.

4. Moore, R.D.; Schoenberg, M.D. 1964. The response of the histiocytes in the lungs of rabbits injected with Freund's adjuvant. Brit. J. Exp. Pathol. 45:488-497.

5. Wanstrup, J.; Christensen, H.E. 1965. Granulomatous lesions in mice produced by Freund's adjuvant. Acta Pathol. Microbiol. Scand. 63:340-354.

6. Galindo, B.; Imaeda, T. 1966. Cellular response to Freund's adjuvant in the rabbit lung. Lab. Invest. 15:1659-1681.

7. Myrvik, Q.N.; Leake, E.S.; Fariss, B. 1961. Studies on pulmonary alveolar macrophages from the normal rabbit: A technique to procure them in a high state of purity. J. Immunol. 86:128-132.

8. Luft, J.H. 1961. Improvements in epoxy resin embedding methods. J. Biophys. Biochem. Cytol. 9:409-414.

9. Pinkett, M.O.; Cowdrey, C.R.; Nowell, P.C. 1966. Mixed hematopoietic and pulmonary origin of "alveolar macrophages" as demonstrated by chromosome marker. Amer. J. Pathol. 48:859-867.

10. Virolainen, M. 1968. Hematopoietic origin of macrophages as studied by chromosome markers. J. Exp. Med. 127:943-952.

11. Low, F.N. 1953. The pulmonary alveolar epithelium of laboratory mammals and man. Anat. Rec. 117:241-263.

12. Schaefer, K.E.; Avery, M.E.; Benirschke, K. 1964. Time course of changes in surface tension and morphology of alveolar epithelial cells in CO_2-induced hyaline membrane disease. J. Clin. Invest. 43:2080-2093.

13. Kikkawk, Y.; Motoyama, E.K.; Cook, C.D. 1965. The ultrastructure of the lungs of lambs. Amer. J. Pathol. 47:877-903.

14. Goldenberg, V.E.; Buckingham, S.; Sommers, S.C. 1969. Pilocarpine stimulation of granular pneumonocyte secretion. Lab. Invest. 20: 147-158.

15. Rosenbaum, R.M.; Wittner, M.; Seager, M. 1969. Mitochondrial and other ultrastructural changes in great alveolar cells of oxygen-adapted and poisoned rats. Lab. Invest. 20:516-528.

16. Svoboda, D.J. 1962. Ultrastructure of pulmonary adenomas in mice. Cancer Res. 22:1197-1201.

17. Svoboda, D.J. 1964. Electron microscopic study and murine pulmonary adenomas. Acta Unio Contra Cancrum 20:1331-1336.

18. Brooks, R.E. 1968. Pulmonary adenoma of strain A mice: An electron microscopic study. J. Nat. Cancer Inst. 41:719-742.

19. Shorthand, J.R.; Darke, C.S.; Crane, W.A.J. 1969. Electron microscopy of desquamative interstitial pneumonia. Thorax 24:192-208.

20. Kuhn, C.; Györkey, F.; Levine, B.E.; Raminez-Rivera, J. 1966. Pulmonary alveolar proteinosis: A study using enzyme histochemistry, electron microscopy and surface tension measurement. Lab. Invest. 15:492-509.

21. Hackett, R.L.; Sunderman, F.W., Jr. 1968. Pulmonary alveolar reaction to nickel carbonyl. Arch. Environ. Health 16:349-362.

Unclassified
Security Classification

DOCUMENT CONTROL DATA - R & D

(Security classification of title, body of abstract and indexing annotation must be entered when the overall report is classified)

1. ORIGINATING ACTIVITY (Corporate author) Department of the Army Fort Detrick Frederick, Maryland 21701	2a. REPORT SECURITY CLASSIFICATION Unclassified 2b. GROUP

3. REPORT TITLE

PULMONARY ALVEOLAR EPITHELIAL CHANGES IN RESPONSE TO FREUND'S ADJUVANT

4. DESCRIPTIVE NOTES (Type of report and inclusive dates)

5. AUTHOR(S) (First name, middle initial, last name)

Charles S. Faulkner II
John R. Esterly

6. REPORT DATE April 1970	7a. TOTAL NO. OF PAGES 25	7b. NO. OF REFS 21
8a. CONTRACT OR GRANT NO. b. PROJECT NO. 1T061101A91A c. Task Work Unit 00-015 d. DD 1498 Agency Access. DA OL 0166	9a. ORIGINATOR'S REPORT NUMBER(S) Technical Manuscript 600 9b. OTHER REPORT NO(S) (Any other numbers that may be assigned this report) CMs 6668 AMXFD-AE-T 49815	

10. DISTRIBUTION STATEMENT

Qualified requesters may obtain copies of this publication from DDC. Foreign announcement and dissemination of this publication by DDC is not authorized.
Release or announcement to the public is not authorized.

11. SUPPLEMENTARY NOTES Pathology Division	12. SPONSORING MILITARY ACTIVITY Department of the Army Fort Detrick Frederick, Maryland 21701

13. ABSTRACT

Observation of lungs of rabbits 3 weeks after intravenous injection of complete Freund's adjuvant indicates that both alveolar cell types (granular pneumonocytes and membranous pneumonocytes) participate in the reaction of the lung to the adjuvant. ~~Our~~ Findings also suggest that these two cell types have a common origin and/or that transformation from one cell type to the other may occur.

14. Key Words

Freund's adjuvant
Pneumonocytes
Pulmonary alveoli
Epithelium
Mononuclear cells
Lung

DD FORM 1 NOV 65 1473 REPLACES DD FORM 1473, 1 JAN 64, WHICH IS OBSOLETE FOR ARMY USE.

Unclassified
Security Classification