UNCLASSIFIED

AD NUMBER

AD840400

NEW LIMITATION CHANGE

TO

Approved for public release, distribution unlimited

FROM

Distribution authorized to U.S. Gov't. agencies and their contractors; Administrative/Operational Use; JAN 1967. Other requests shall be referred to Department of the Army, Fort Detrick, AttN: Technical Release Branch/TID, Frederick, MD.

AUTHORITY

SMUFD D/A ltr, 15 Feb 1972

THIS PAGE IS UNCLASSIFIED

AD840400

TRANSLATION NO. 1947

DATE: 5 January 1967

DDC AVAILABILITY NOTICE

Reproduction of this publication in whole or in part is prohibited. However, DDC is authorized to reproduce the publication for United States Government purposes.

D D C
OCT 3 1968

STATEMENT #2 UNCLASSIFIED

This document is subject to special export controls and each transmittal to foreign governments or foreign nationals may be made only with prior approval of Dept. of Army, Fort Detrick, ATTN: Technical Release Branch/TID, Frederick, Maryland 21701

13

Best
Available
Copy

THE DEVELOPMENT OF PEYER'S PATCHES

Zeitschrift für Anatomie
und Entwicklungsgeschichte
(Journal of Anatomy and Ontogeny)
Vol. 117 (1953) pages 26-35

G. Eberl-Rothe
P.A. Langegger

Introduction

Previous studies of intestinal diverticula and Peyer's patches have left some questions open, and it is the purpose of this article to answer those questions. The present study was done as a continuation of the published articles of Patzelt (1931) and Langegger (1939), to supplement and extend the results of those investigations.

Treatment of the Material

Over forty series of human embryos varying in age from 11 to 147 mm in length were examined, mostly hematoxylin-eosin stained sections, but also including preparations with iron hematoxylin, Mallory, orcein, and Rio Hortega staining. Besides the series, preparations of the whole human intestine were made by Voss's method for the study of the distribution, number, and size of the diverticula and Peyer's patches. The whole intestine, separated from the mesentery, was cut open longitudinally along the line of attachment of the mesentery, carefully emptied of its contents and cleaned. It was then stained with hemalum and subsequently differentiated in dilute acetic acid or hydrochloric acid. It is absolutely necessary to use the greatest care in this, since the completely unfixed intestine is very slippery, soft, and easily torn. It is recommended that very large vessels be chosen for this work, so that in the first place the intestine will not be unevenly stained because the individual loops lie too close upon each other and in the second place it is easier to move it from one vessel to another. It is very desirable for such studies to wind the intestine spirally around a glass rod and subject it

GRAPHIC NOT REPRODUCIBLE



Figure 1. Different graphic representations of Peyer's patches after staining of the small intestines with hemalum. The point markings represent the size, number, arrangement, and area of distribution of the Peyer's patches. Here two small intestines of different lengths are represented by the same length.

to staining in that arrangement. Of course the mucous membrane side is turned outward. After differentiation with acetic acid (until only the Peyer's patches remain stained) the preparation is put into alcohol (96%) and so can be kept for a long time; the staining is preserved for years, especially in the dark. Even after a few days the advantage of the alcohol treatment, which also serves for fixing, shows itself in the fact that the intestine is somewhat hardened and consequently is easier to study. It can be spread out on a glass plate and examined bit by bit. The size, distribution, and number of Peyer's patches in more than twenty small intestines treated by this method were recorded on paper strips of equal length, and an overall picture of as many individuals as possible of the most widely different ages thus obtained very quickly and extremely simply (Figure 1). The procedure was that the intestines were laid out full length and their significant details transferred to paper strips laid beside them. It was then much easier to work with the copies thus obtained when making measurements and comparisons than with the fragile and easily damaged intestines themselves.

In the same way the same features were transferred to paper on the basis of the serial sections. In order to get a better grasp of all these drawings, all data were calculated to a relatively equal length. -- Wax models were made of some of the preparations.

Some Studies and the Results Previously Published

We start with the fact that even in the untreated intestine it is possible to discern, and better still after staining with hemalum (Voss), two completely different types of Peyer's patches (Figures 2a and 2b). This difference is confirmed by microscopic examination and by the study of the development. One type (Figure 2a) is characterized by an irregularly bounded aggregation of individual follicles which form unordered, unsystematic groups. At the periphery of these groups of follicles is found a diffuse lymphoreticular tissue, which gradually splits up and merges into the surrounding area. But this tissue is clearly distinguishable from that which is found in the

GRAPHIC NOT REPRODUCIBLE



Figure 2. a) Peyer's patch in an opened section of intestine, consisting of an irregularly and not precisely bounded aggregation of single follicles (type 1). Complete staining with hemalum. b) Peyer's patch of the same intestine, definitely and exactly marked off from its surroundings and constituting a uniform structure (type 2).

tonsils and has been consistently described for the tonsilar crypts by Swain (1866), Stöhr (1891), Hammar (1902), Jurich (1912), and Foerster (1923). For here there are not only secondary nodules (nuclei, reaction centers) lying in the lymphoreticular tissue, but single follicles merged into loose groups, and this difference also manifests itself in a comparison of the development of tonsils and of this type of Peyer's patch. The second type of Peyer's patch, which is immediately noticeable in the examination of the small intestine by its mere predominance in number, is constrained by a well preformed morphological base to maintain a definite form and so can be recognized as a precisely delimited structure (Figure 2b). It reminds one of the description given of the Peyer's patches by Brücke back in 1854, in which he says that the Peyer's patch may be conceived of as a split lymph nodule which has been pulled apart on a plane. The demarcation of this second type of Peyer's patch is predominantly formed by a follicle-free zone which is raised above its surroundings and stands out clearly from them. Often the periphery of the plates is actually formed of a wall or a marginal fold, which further emphasizes its demarcation. Patzelt conjectured in 1931 that this kind of Peyer's patches are connected with the numerous small diverticula which are observable during the development of the small intestine and become unnoticeable along with the Peyer's patches, and supported this with older developmental stages from the literature and his own findings. Elze (1909) brings out that a distinction should be made between the dorsal diverticula of the upper intestinal region and the ventral ones which later develop caudally. He recognized even at that time that these formations in the ileum have nothing to do with sensory buds or rudimentary glands. Caler and Lewis (1911) counted 32-53 such diverticula, and found relatively fewer in the jejunum than in the ileum. Similar formations have also been found in the duodenum, where they show up especially plainly after removal of the epithelial covering. But these have

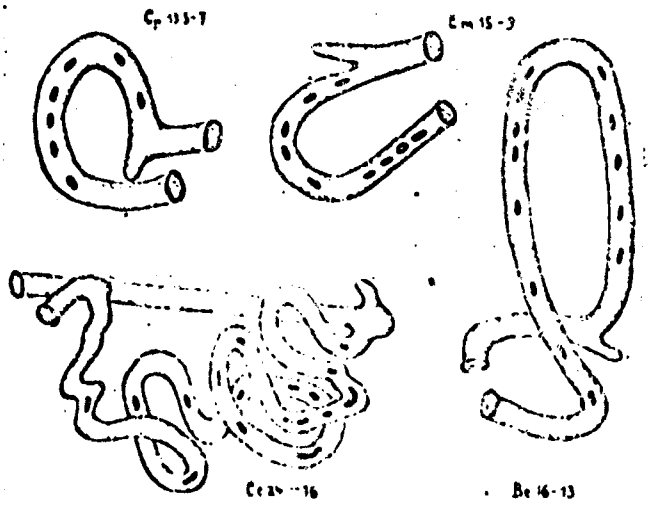

Figure 3. View of the multiplication of embryonic intestinal diverticula with longitudinal growth of the small intestine. At 13.5 mm greatest length, 7, at 15 mm 9, at 16 mm 13, and at 24 mm 16 diverticula. (Drawn from reconstructions from serial sections.)

nothing in common with our diverticula, for the study of older stages never reveals Peyer's patches, but sometimes scattered rudimentary glands (e.g. pancreas) which are traced to the above-mentioned formations. In several series we were able to count over forty true diverticula and show that they first become visible in human embryos of 11 mm in length (Langegger 1939) and treble in number during the growth to 30 mm (Figure 3). This will be discussed in detail later.

Corresponding to the position of the diverticula, the Peyer's patches with few exceptions are also situated antimesenterially. An exception is the most caudally situated patch, which is close to the transition to the large intestine and may constitute an almost closed circular lymphatic ring inclosing the entire propria; another exception, as mentioned above, is represented by those sparse Peyer's patches (type 1) which are not situated at the base of the diverticula. They may be recognized directly by the fact that in the opened intestine they lie apart from the central line which connects almost all Peyer's patches in a straight line. In following along this line one is struck by the fact that nearly all the Peyer's patches are situated where the vessels supplying the intestine have already branched out into their smaller branches.

The first appearance of the diverticula coincides with the development of the umbilical fissure, and the first diverticula always lie at the apex of the umbilical loop, which is already situated in the fissural sac (Figure 4). During the

GRAPHIC NOT REPRODUCIBLE

Figure 4 (above). Section through the apex of the umbilical loop of an embryo 18 mm long. Upper left and lower right, one diverticulum each in the transversely cut wall of the intestine.

Figure 5 (right). First rudimentary beginning of a diverticulum, something like a sensory bud. Transverse section through the ileum of a human embryo 11 mm in greatest dimension. Hematoxylin-eosin staining.

further growth it is impossible to tell whether the diverticula merely change their shape and achieve their later characteristic appearance because of the growth in length of the intestine or whether other growth factors play a part.

That the number of both diverticula and Peyer's patches varies in individuals of the same age and that Peyer's patches probably undergo involution was brought out in Langegger's first article (1939). There is no relation at all between age and number, for we found e.g. 42 Peyer's patches in a child a few days old, 25 in a 1 1/2 month old child, 34 in a 5 month old child, and 33 in a 72 year old man. On the average the number fluctuates between 55 and 20, or approximately in the range of doubling.

From the relatively large amount of material available for examination it can also be seen that the growth of the intestine is by no means uniform, but that the segment containing Peyer's patches grows more in length than the part free of diverticula. Thus e.g. in embryo E7, greatest length 31 mm, the part containing diverticula is 48% of the total length of the small intestine, while in children and adults the part containing Peyer's patches is 75% of the small intestine (measured on 16 small intestines of varying age). [Translator's note: The photograph from which this translation is prepared is partially illegible at this point, so that a few words of the last sentence may be incorrect.]

Now if we first follow the growth of a diverticulum, we find upon close examination in detail the following: Its first rudiment develops intraepithelially. By an especially dense

aggregation of cells a place is marked out which is similar to an endoepithelial gland anlage or a sensory bud. At that point there is also a slight depression of the epithelium toward the lamina propria, so that the lumen of the intestine, originally circular in cross section, appears somewhat distorted (Figure 5). In the next stage this manifests itself as an infolding of the inner surface forming a secondary lumen, connected with the intestinal lumen already existing by a bottleneck-like connective



Figure 6. Longitudinal section through the ileum of a human embryo 27 mm in length. Diverticulum with definite peripheral fold. Bouin, iron-hematoxylin-eosin. 100-fold magnification. (From Patzelt, 1931.)

part. In this way a dilation has developed which has become a diverticulum, and at the same time the originally endoepithelial formation is depressed into the lamina propria of the intestinal tube. Through further growth and the expansion of the intestinal lumen the originally bottleneck-like connection becomes more and more stretched and the entire diverticulum expanded in width. There remains a narrow fold of the mucous membrane which surrounds the short connective passage between intestinal and diverticular lumen, the remains of which can be found even later designated as a peripheral fold or slipper-shaped fold (Figure 6). This peripheral fold, as may be seen in Figure 6, may give a completely symmetrical picture; or in the further course of growth it may lose its symmetry by the caudal side of the diverticulum's becoming more elongated through greater growth. The more developed side of the pocket thus formed thus simultaneously indicates the direction of growth of the intestine.

Often the diverticulum is like a more tubular process of considerable size, e.g. in the embryo of 31 mm the largest is 1.28 mm long (Figure 7). At about the same size the diverticulum acquires an irregular surface relief. This phenomenon is connected with the development of the villi and crypts, which sets in in embryos of about 19 mm in length (Figure 8), and prepares the way for its eventual absorption and incorporation

GRAPHIC NOT REPRODUCIBLE

GRAPHIC NOT REPRODUCIBLE

Figure 7. Wax model of a human small intestine; embryo of 31 mm greatest length. Right, the intestinal loop convolution situated in the fissural sac, with black outlined diverticula, of which the one in the center is definitely elongated into a tubular shape.

Figure 8. Human small intestine with diverticulum cut transversely (slipper-shaped fold), which by the formation of villi and crypts has made its wall similar to the intestinal and so prepared for its gradual incorporation into the latter. Embryo of 62 mm. Iron hematoxylin-eosin.

GRAPHIC NOT REPRODUCIBLE

into the surrounding intestinal mucous membrane. This is the time when the pictures of embryonic diverticula disappear from the relief of the mucous membrane of the small intestine, giving rise to numerous theories concerning the significance of the diverticula. The floor of the diverticulum behaves in this stage in the same way as the intestine itself; its epithelium develops like the intestinal epithelium, so that villi and crypts develop in it; the lumen of the intestine becomes larger and larger, and with the growth in surface of the intestine the opening of the diverticulum is dilated, the surrounding marginal fold becoming less and less evident. By very careful searches of the serial

sections of the corresponding age it is possible to detect the diverticula by means of the remaining marginal folds. Th we succeeded in finding six diverticula in an embryo of 147 mm in length, though at that stage there is considerable difficulty in detecting them. According to Keibel (II, page 373), F.P. Johnson was still able to find diverticula in a human fetus 134 mm in length; this shows that diverticula may still be found even after the appearance of villi and crypts, although by birth they have disappeared. In 1901 Fischer quoted Lewis to the effect that "no case has yet been described where diverticula were found in a newborn infant."

At this stage of development it is to be observed that throughout the mucous membrane, and especially at the places where diverticula are found in the process of absorption, an active accumulation of lymphocytes takes place, a phenomenon characteristic of the intestinal wall in this stage. At about the fifteenth week lymphocytes form solitary lymph nodules, which immediately after their appearance are to be found in groups in the intestine, as they are in other parts of the body as well. The origin of Peyer's patches thus falls in this period. Koelliker (1861) did not find them until the sixth month, Baginsky (1882) describes them in human embryos only four months old, Lewis (1911) in an embryo of 240 mm in length. or approximately in the period between the other two. Hellman (1921) points out that the beginning of Peyer's patches is indicated in the vascular network of the submucosa before the lymphoreticular tissue of the propria, strictly defined, has yet been developed. Patzelt (1931) states that the lymphoreticular tissue of the intestine is plainly recognizable in the fifth month, and that Peyer's patches then begin to develop in the sixth and seventh months. Let us also mention at this point that during the development of the vermiform appendix especially long and large crypts are to be observed, and that among these particular crypts the follicles develop in the same way as is the case in the region of the diverticula of the intestine (Patzelt 1931, Ratzenhofer 1942).

Even in this stage many Peyer's patches show the often described marginal fold which so clearly points to the connection with the diverticula. Such a (slipper-shaped) marginal fold was described in detail by Schiller (1915) in the case of the tapir; we mention it here because it is striking in this case that in spite of the presence of a fold, which tells in favor of development on the basis of a diverticulum, the Peyer's patches consist of diffusely distributed follicles whose association is hardly recognizable. If it is permissible to compare these conditions in man and the tapir at all, this appearance must be due to a poor state of preservation; we do also know that under certain circumstances the lymphatic tissue of the Peyer's patches can be greatly reduced. Hyrtl (1875) mentions that in long illnesses the Peyer's patches are so to speak

GRAPHIC NOT REPRODUCIBLE



Figure 9. Peyer's patch with definite marginal fold, from Berres, Anatomie der Mikropischen Gebilde des Menschlichen Körpers (Anatomy of the Microscopic Structures of the Human Body), 1837.

eaten away by the intestinal cavity, so that they appear as sharply outlined openings, and it may perhaps be to this appearance that the older designation "Peyer's glands" is to be attributed. It is also worth noting from the above-mentioned article that Schiller finds one edge of a fold slipper-shaped and the other part of the edge bridge-shaped, so that the Peyer's patch seems to be thrusting through the slipper. Jakobshagen (1915), whose attention was called to the matter by Schiller's work, follows this observation with his own, and describes Peyer's patches 5 mm in size, also surrounded by marginal folds, in human embryos 19 and 26 mm in length. He interprets the marginal folds as secondary formations and suggests that they originate in the coalescence of the villi surrounding the patches. But on this assumption we should often find intermediate stages which would confirm this view, and at least in the material we had available for examination such was not the case. Jakobshagen observed that the larger Peyer's patches were surrounded by low folds and vice versa. Once the marginal folds are correctly understood, that is easy to understand. But in the literature there are many older reports on the borders of Peyer's patches. Thus Henle (1866) mentions a marginal fold in the newborn, Berres gives an illustration of one back in 1837 (Figure 9) which he explains by the coalescence of big intestinal villi, and L. Böhm in 1835 describes the Peyer's "glands" in a child of 10 months as surrounded by a separate covering or with a lamella stretched over them.

According to our present knowledge this marginal fold so variously described is nothing other than the remnant of that fold of the mucous membrane which borders the connecting passage between the intestinal and diverticular lumina. As the diverticula become larger and flatter this marginal fold becomes less and less conspicuous and in most cases disappears completely,

so that the diverticula are submerged in the relief of the intestinal wall. But where remnants of such a fold remain in existence they naturally lie at the periphery of the Peyer's patches, border upon them throughout areas of varying size, and may in extreme cases bridge over the Peyer's patches. Figure 8 shows such a mucous membrane bridge over a diverticular recess in an embryo of 62 mm in length.

These marginal or slipper-shaped folds thus constitute the morphological connecting link between the individual diverticula and the Peyer's patches which spring from them as a base. The embryonic intestinal diverticula are the epithelial base for the mensenchymal intestinal tonsils that develop around them.

The fully developed patches, insofar as they show any relationship with the diverticula by their marginal folds or by their position with respect to the mesentery, can of course be made up of few or many solitary follicles, and so may exhibit wide variation in size. Just as there is no relationship between age and number of the Peyer's patches, neither is it possible to draw from the size any conclusion as to the number. Only a few patches may be particularly striking for their size and still no great number be present, or again all the patches present may not vary greatly in size. There may be constitutional differences involved here, as in lymphatic tissue in general. In the material we had available for examination the largest number of patches we were able to find was 58.

Let us particularly point out here that very small Peyer's patches can always be found which are still clearly observable macroscopically in whole preparations, since they vary within a range of size of 1/2 to 5 mm. As we were able to confirm, they are present in widely varying number, so that for example in a total number of 57 Peyer's patches there were nine such, and in the intestine mentioned above with 58 Peyer's patches there were 32 of the last-mentioned type. They may lie scattered individually among the large patches, or several of equal size may be together in groups. It also occurs that one such small patch is situated alone close beside a very large extended one. But these small patches are always clearly marked out, so that they can be definitely classed with the second type of our patches, and are usually roundish and rarely oval. The large patches, on the other hand (with diameter above 5 mm), are usually very long-extended ovals and more rarely short-oval and only occasionally round.

Some data will exemplify what has been said: e.g. intestine 1 shows 42 Peyer's patches, the largest showing a length of only 12 mm, while intestine 27, with 34, contains the largest patch, of 40 mm in length. But we cannot simply conclude from this that the size of the Peyer's patches makes up for the smaller number, because we see that in intestine 1 the total length

of the Peyer's patches makes up 18% of the small intestine, while all the patches of intestine 27, which has larger Peyer's patches, make up only 7.3% of the length of the small intestine. This does not rule out the possibility that the total volume may work out compensatorily.

The total area was computed by Hellman (1921) as 129 mm. The suggestion is also his that we designate follicle aggregates from 1/2 cm^2 up as Peyer's patches.

The Peyer's patches start in the small intestine in the region of the plicae circulares, the regularity of which they interrupt. Toward the end of the small intestine they are surrounded by more and more densely strewn solitary follicles, which extend from there on throughout the large intestine, so to speak replacing the Peyer's patches.

Summary

On the basis of numerous serial sections of human embryos and whole intestines from individuals of the most varied ages, the development, number, and size as well as the distribution and arrangement of the Peyer's patches have been studied and the findings attested by various measurements, for which a special technique of our own was used. Two types of Peyer's patches were found, the difference between which is due to their development, but which are to be distinguished also by their position with respect to the mesentery and by their morphological differences. It was also found that the part of the embryonic intestine occupied by diverticula makes up a relatively smaller part of the whole small intestine than the corresponding part later occupied by Peyer's patches. This permits the conclusion that the part of the small intestine that is free of diverticula has a slighter growth in length than the rest.

Bibliography

Baginsky, A., Virchows Archiv (Virchow's Archives), Vol 89, 1882, page 64.

Berres, J., Anatomie der Mikroskopischen Gebilde des Menschlichen Körpers (Anatomy of the Microscopic Structures of the Human Body), Gerold, Vienna, 1837.

Böhm, L., De Gland. Intest. Struct. Penitiori (Concerning the Innermost Structure of the Intestinal Glands), 1835.

Brücke, F., Denkschriften der Wiener Akademie (Memoirs of the Viennese Academy), Vol 2, 1850, page 21.

Brücke, E., Denkschriften der Akademie der Wissenschaften zu Wien, Mathematisch-Naturwissenschaftliche Klasse (Memoirs of the Academy of Sciences at Vienna, Mathematical and Natural Sciences), Vol 6, 1854, page 99.

Elze, C., Dissertation, Freiburg im Breisgau, 1909.

Fischer, M.H., Journal of Experimental Medicine, Vol 5, 1901, 1901, page 332.

Hammar, J.A., Anatomischer Anzeiger (Anatomical Intelligencer), Vol 22, 1902, page 221.

Hellman, T.J., Beiträge zur Pathologischen Anatomie (Contributions to Pathological Anatomy), 1921.

Henle, J., Handbuch der Systematischen Anatomie des Menschen (Manual of Systematic Human Anatomy), Vol II, Brunswick, 1866.

Hyrtl, J., Lehrbuch der Anatomie des Menschen (Textbook of Human Anatomy), Vienna, 1875.

Jacobshagen, E., Anatomischer Anzeiger, Vol 48, 1915, page 65 [cited in the text with the spelling Jakobshagen].

Johnson, F.P., cited in Keibel-Mall's Handbuch der Entwicklungsgeschichte des Menschen (Manual of Human Ontogeny), Vol II, Leipzig, 1910, page 372.

Keibel, F., Verhandlungen der Anatomischen Gesellschaft zu Genf (Transactions of the Anatomical Society at Geneva), 1905.

Keibel, F., Anatomischer Anzeiger, Vol 27, page 39.

Koelliker, A., Entwicklungsgeschichte des Menschen und der Höheren Tiere (Ontogeny of Man and the Higher Animals), Leipzig, 1861.

Langegger, P.A., Verhandlungen der Anatomischen Gesellschaft u. Anatomischer Anzeiger, Ergänzungs-Heft (Transactions of the Anatomical Society and Anatomical Intelligencer, Supplementary Number) 88, 1939.

Lewis, F.T., cited in Keibel-Mall's Handbuch der Entwicklungsgeschichte des Menschen, Leipzig, 1911.

Lewis, F.T. and Thyng, F.W., American Journal of Anatomy, Vol 7, 1908, page 505.

Passow, A., Inaugural Dissertation, Berlin, 1883.

Patzelt, V., Zeitschrift für Mikroskopisch-Anatomische Forschung (Journal of Histological Research), Vol 27, 1931.

Ratzenhofer, M., Zeitschrift für Mikroskopisch-Anatomische Forschung, Vol 52, 1942, page 87.

Schiller, A., Anatomischer Anzeiger, Vol 48, 1915, page 54.

Stöhr, Ph., Zeitschrift für Mikroskopische Anatomie (Journal of Microscopic Anatomy), Vol 33, 1889.

Stöhr, Ph., Ergebnisse der Anatomie (Advances in Anatomy), Vol 1, 1891-92, page 173.

Voss, H., Zeitschrift für Anatomie (Journal of Anatomy), Vol 70, 1923, page 317.