THE JOURNAL OF TRAUMA
Vol. 10, No. 8
Printed in U.S.A.
Copyright © 1970 by The Williams & Wilkins Co.

RESPONSE TO BLUNT CHEST INJURY: A NEW EXPERIMENTAL MODEL

ROGER V. MOSELEY, MAJOR, MC, JEROME J. VERNICK, MAJOR, MC, AND DONALD B. DOTY, MAJOR, MC

From the Division of Surgery, Walter Reed Army Institute of Research, Walter Reed Army Medical Center, Washington, D. C.

AD717927

Reproduced by
NATIONAL TECHNICAL
INFORMATION SERVICE
Springfield, Va. 22151

DISTRIBUTION STATEMENT A
Approved for public release;
Distribution Unlimited

DDC
RECEIVED
FEB 10 1971
C

12

THE JOURNAL OF TRAUMA
Vol. 10, No. 8
Copyright © 1970 by The Williams & Wilkins Co.
Printed in U.S.A.

RESPONSE TO BLUNT CHEST INJURY: A NEW EXPERIMENTAL MODEL

ROGER V. MOSELEY, MAJOR, MC, JEROME J. VERNICK, MAJOR, MC, AND DONALD B. DOTY, MAJOR, MC

From the Division of Surgery, Walter Reed Army Institute of Research, Walter Reed Army Medical Center, Washington, D. C.

Pulmonary insufficiency continues to be a major cause of death following trauma of many types. In combat casualties, direct injury to the lung is the most common cause of arterial hypoxemia (11), though contusion of the chest wall by a high velocity bullet may actually produce a greater pulmonary injury than when the lung is penetrated (5). Similarly, the familiar civilian injuries that occur when the chest is crushed against the steering wheel may produce severe contusion of the underlying pulmonary parenchyma while the chest wall remains intact. An experimental method for producing a standard injury to the lung through the intact chest wall has been developed, and the acute changes in cardiopulmonary function following injury have been studied. The physiologic changes associated with healing of the injury have been documented.

MATERIALS AND METHODS

Thirty dogs were used in this investigation. The pilot study group consisted of 10 small beagles, weighing 7 to 10 kg. These animals were unable to tolerate the injury in many cases, but served to perfect the technique and to evaluate methods of resuscitation. The principal experimental group consisted of 20 large mongrels or foxhounds weighing 22 to 25 kg. In conducting this research, the investigators adhered to the *Guide for Laboratory Animal Facilities and Care*, as promulgated by the Committee on the Guide for Laboratory Animal Facilities and Care of the Institute of Laboratory Animal Resources, National Academy of Sciences—National Research Council.

Address for reprints: Roger V. Moseley, Major, MC, Department of Experimental Surgery, Division of Surgery, Walter Reed Army Medical Center, Washington, D. C. 20012.

The animals were anesthetized with pentobarbital sodium 30 mg/kg, and the airway was maintained with a Carlens endotracheal tube modified to isolate each main stem bronchus completely without occluding the upper lobes. Catheters were placed in the abdominal aorta and right ventricle through incision in the femoral vessels. Calibrated pressure transducers and limb leads were used to record arterial and right ventricular pressures, and the electrocardiogram, on a Sanborn multichannel recorder.

After an initial period of equilibration as the animal breathed room air, central venous and arterial blood samples were drawn into heparinized syringes for determination of hematocrit and partial pressure of oxygen (pO_2), carbon dioxide (pCO_2), and the pH with an Instrumentation Laboratories Model 113 Blood Gas Analyzer. The oxygen content of the blood was then calculated with the nomogram of Severinghaus (14). Respiratory rate was recorded and minute volume measured with a Wright respirometer. Cardiac output was determined by bolus injection of 2.5 mg of indocyanine green dye into the right ventricular catheter, while blood was simultaneously withdrawn from the arterial catheter by a Harvard constant-rate pump. The dye curve was recorded on a Beckman cardiodensitometer and the cardiac output derived from the area under the curve.

These studies were then repeated after the animal had spontaneously breathed 100% oxygen for 15 min and again after 15

min of respiratory assistance given by a volume-controlled respirator with 100% oxygen. Physiologic intrapulmonary shunt under each condition was then calculated by a modification of the Fick principle from the arterial and venous oxygen content, and an assumed value for partial pressures of oxygen in pulmonary capillary blood of 105 mm Hg on room air and 670 mm Hg on 100% oxygen. The oxygen content of expired air was checked to insure adequate elimination of nitrogen when 100% oxygen was breathed.

Contusion of the chest wall was then produced. A 2-inch thick foam rubber pad was securely fastened in the subaxillary portion of the right side of the chest to cushion a steel plate, 3 inches in diameter, which was placed on the pad. A Cash-X captive bolt pistol (Accles and Shelvoke, Ltd., Talford St. Works, Birmingham 6, England) was then held securely against the steel plate while a 1¼ gr cartridge was discharged. This was always fired at the end of a spontaneous inspiration, to produce a consistent effect, as emphasized by Hopkinson, Border, and Schenk (9). The resultant blow to the chest wall created a contusion of the underlying pulmonary parenchyma with a characteristic radiologic picture and a reproducible change in pulmonary and cardiac function.

The sequence of studies outlined above was then repeated during the first and second hours after injury. Follow-up studies were performed in seven animals at 2 days, eight animals at approximately 1 week, two at 10 days, and two at 14 days to evaluate changes during the healing period. After completion of the second study the animal was usually sacrificed and representative sections of the lung taken for histologic examination, though some animals were studied a third time.

RESULTS

In the pilot study most animals died within hours of the contusion and survival studies were not possible. In the second group of 20 larger animals, one died 24 hr later due to bilateral hemopneumothorax and five were sacrificed acutely for study of the histopathology of the injury. The remaining 14 recovered well and appeared in good health within a few days of injury.

RADIOLOGIC CHANGES

A hazy density appeared in the lung at the site of injury within minutes after contusion (Fig. 1 A, B). This gradually increased in size but usually remained circumscribed except in the small animals when the entire right lung was sometimes opacified. There was a shift of the heart shadow and mediastinum to the right indicating atelectasis, while the left lung usually remained normal. Clearing of the opacified lung was often apparent within 2 days of the injury, and by a week the lung was almost normal. There were no injuries to the bony thorax, except for a single posterior rib fracture in one dog.

PATHOLOGY

Animals sacrificed within hours of injury showed extensive intrapulmonary hemorrhage extending from the site of injury and involving principally the dependent portions of the right lung (Fig. 2A). There was a circular area of hemorrhagic atelectasis adjacent to the position of the metal plate, and along the posterior portion of the lung adjacent to the spinal column, which failed to re-expand when the lung was passively inflated. The surrounding lung tissue was hemorrhagic and atelectatic, but expanded readily with gentle insufflation of air. The bronchial airway on the right side was always filled with blood. The left lung usually appeared normal unless the Carlens tube was incorrectly placed, allowing blood to be aspirated from the opposite side with resultant patchy consolidation posteriorly. Healing of the lung occurred within a 10-day period so that virtually normal appearance was restored (Fig. 2B) except for some scarring in the area directly under the site of external contusion.



FIG. 1. A. Normal lung before contusion. B. Two hours after contusion, a hazy density appears at the site of contusion in right lower chest and the mediastinum is shifted to the right.

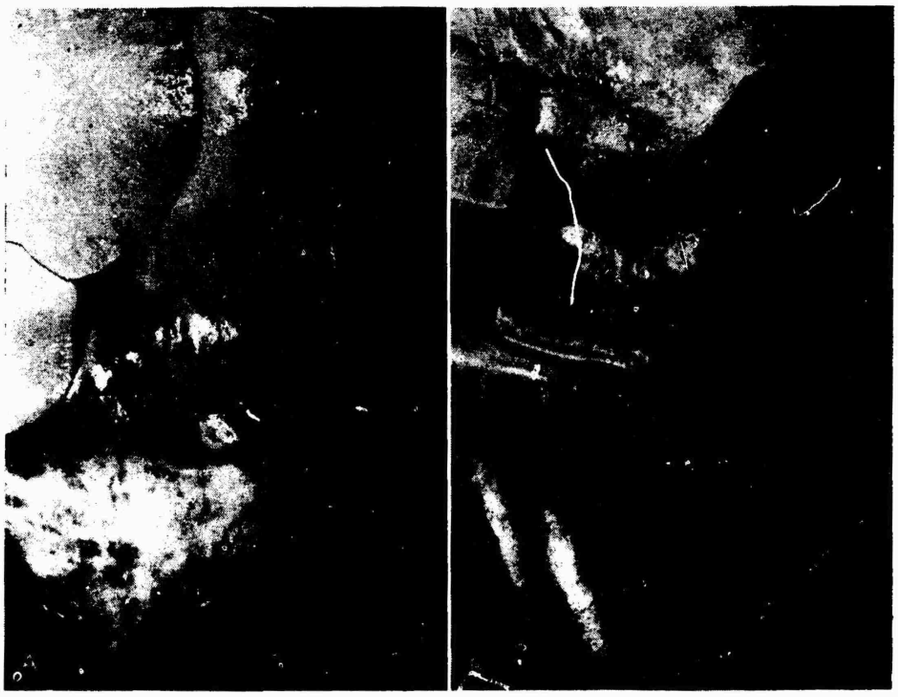

FIG. 2. A. Gross appearance of the lung 2 hr after contusion. A dense area of hemorrhagic atelectasis is seen at the site of contusion (arrow). The lower lobe shows diffuse patchy edema and atelectasis, due in part to aspiration of blood into dependent areas of the lung. B. One week after injury the lung appears virtually normal except for a small contracted scar, barely visible on the lung surface (arrow).

FIG. 3. A. Within a few hours of contusion there is hemorrhage into alveolar spaces, though alveolar walls appear intact. B. Two days after contusion early organization is present. C. Ten days after contusion healing is almost complete except for a small area of dense scar as shown in D.

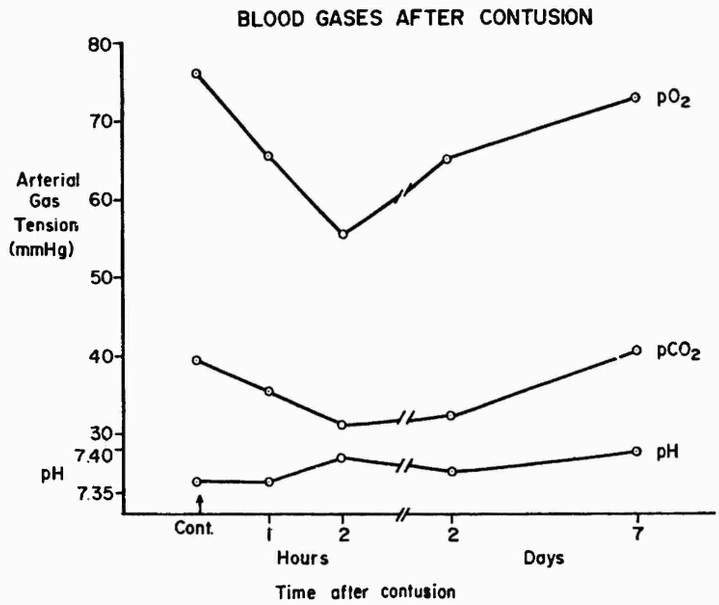

FIG. 4

Histologic sections of the lung confirmed the initial appearance of intrapulmonary hemorrhage (Fig. 3A). Alveolar walls appeared to be intact. This was indistinguishable from that seen in an otherwise normal lung after instillation of 30 ml of blood into the right main stem bronchus. Two days after injury, there was infiltration of polymorphonuclear leukocytes and giant cells with beginning resorption of blood (Fig. 3B). Seven to 10 days after injury, healing was almost complete (Fig. 3C). A few patchy areas of extravasated blood persisted, but alveolar architecture was essentially normal. In the scarred area of the lung directly beneath the steel disk there was fibrosis, but this was the only place where apparently irreversible changes had occurred (Fig. 3D). An additional interesting finding, sometimes seen early after injury, was a small patch of myocardial contusion, usually at the junction of the superior vena cava with the right atrium. Histologic sections confirmed this to be a site of hemorrhage into the wall of the heart.

BLOOD GASES

These changes are illustrated in Figure 4. There was a decrease in mean arterial pO_2 from a control level of 76 mm Hg to 55 mm Hg at 2 hr after contusion. A slight improvement occurred at 2 days and by 1 week after injury, arterial pO_2 had returned to control levels. A decrease in mean arterial pCO_2 persisted for the first 2 days and returned to normal in 1 week. Mean control value for pH was somewhat below accepted normal values, but subsequently it rose in reciprocal relationship to the pCO_2. When 100% oxygen was breathed, there was a sharp fall in mean pO_2 from 440 mm Hg before contusion to 160 mm Hg 2 hr after injury (Fig. 5). Once again, values had returned to normal levels in 1 week.

The physiologic intrapulmonary shunt was greater than normal during the control period prior to contusion. Following contusion there was a dramatic further increase (Fig. 6). This was maximal at 2 hr, showed some improvement at 2 days, and returned to normal by 1 week. Although the respirator usually produced a decrease in shunting both during the control period and after contusion, this change was not statistically significant, due to the great variation among the animals. In two animals, the instillation of 30 ml of blood into the right main stem bronchus produced a fall in pO_2 to 89 mm

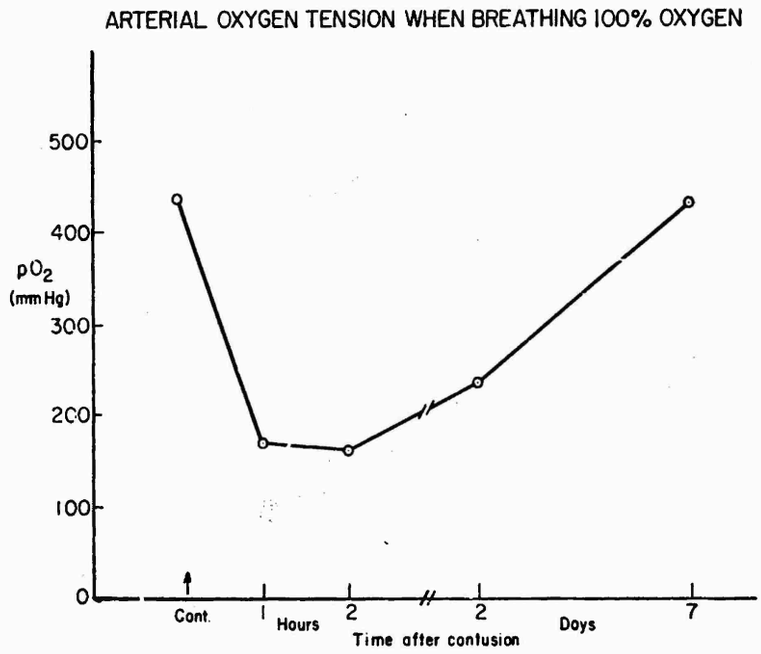

FIG. 5

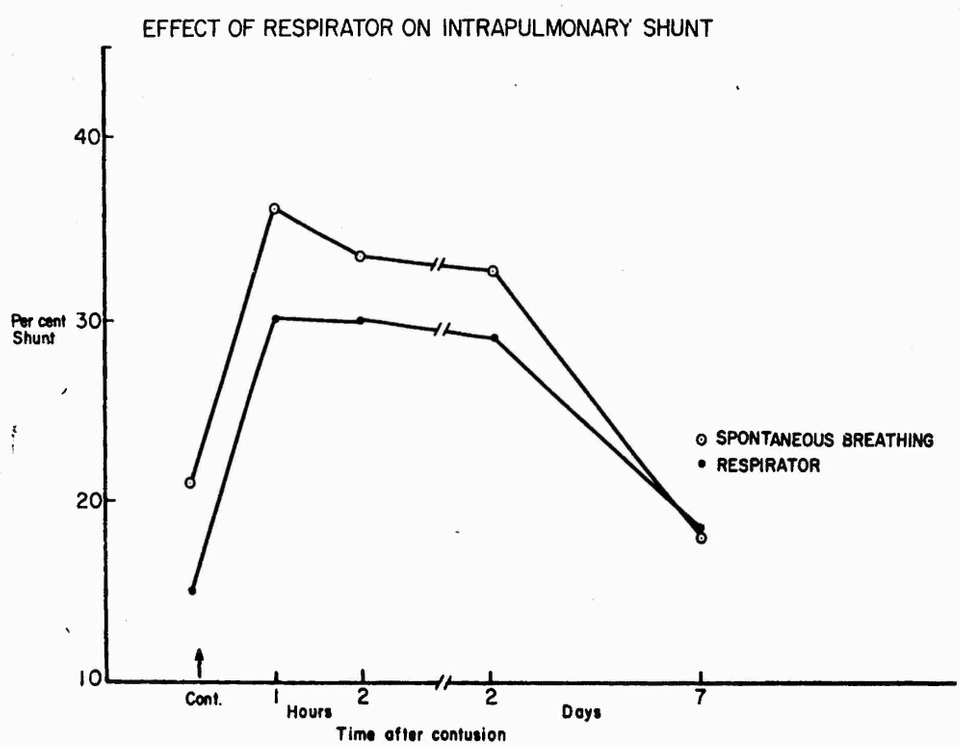

FIG. 6

Hg on 100% oxygen. There was an acute increase in shunt from 15% to 65%.

RESPIRATORY MECHANICS

A brief period of reflex apnea immediately followed injury. Spontaneous respirations returned within 1 min, and thereafter a sharp increase occurred in respiratory rate which was sustained during the first 2 hr after injury (Fig. 7). At first this increase in rate was associated with a slight decrease in tidal volume, but fairly normal minute

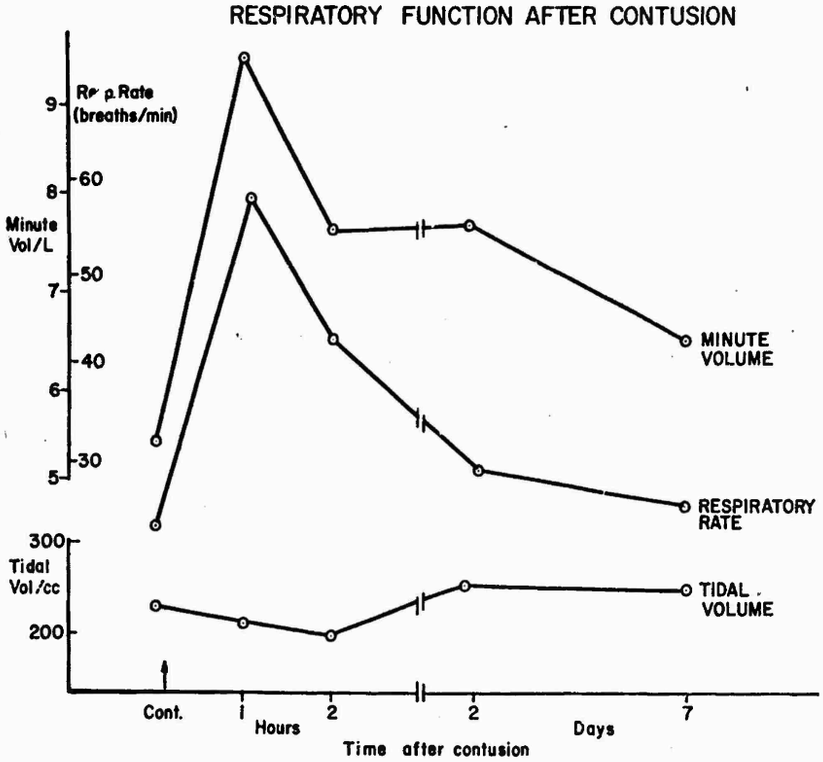

FIG. 7

volume. Two days after injury, tidal volume and respiratory rate were almost normal, but minute volume was still increased. By the end of 1 week, all parameters had returned to the normal range.

HEMODYNAMICS

Severe cardiac arrhythmias with conduction defects and increased ventricular irritability were common immediately after contusion, and there was an associated sharp decrease in both arterial and right ventricular pressures (Figs. 8, 9). These pressures usually rose spontaneously to acceptable levels within a few minutes, although even at 2 hr after contusion they were still lower than control levels. The period of arrhythmia was followed by return of sinus rhythm at a slightly slower rate, so that 1 min after contusion mean heart rate was 168 beat/min compared with a control rate of 197 beat/min. This slowing could be prevented by atropine, and was presumably a result of vagal stimulation. Immediately following injury there was a sharp decrease in cardiac output to less than 50% of control levels, and it remained at this level during the first 2 hr. Two days after injury, although arterial and right ventricular pressures had returned to normal, cardiac output was still slightly, but not significantly ($p = 0.1$) less than normal. This remained true a week later. Mechanically assisted ventilation caused an insignificant decrease in cardiac output even at extremes of rate and tidal volume.

DISCUSSION

The outstanding physiological consequences of the blunt injury to the chest produced in this study were arterial hypoxemia and decreased cardiac output. Some of the changes were partly obscured because many of these experimental animals had hypoventilation with arterial hypoxemia and a significant degree of shunting prior to contusion. This was probably due to the anesthetic agent, since barbiturates alone

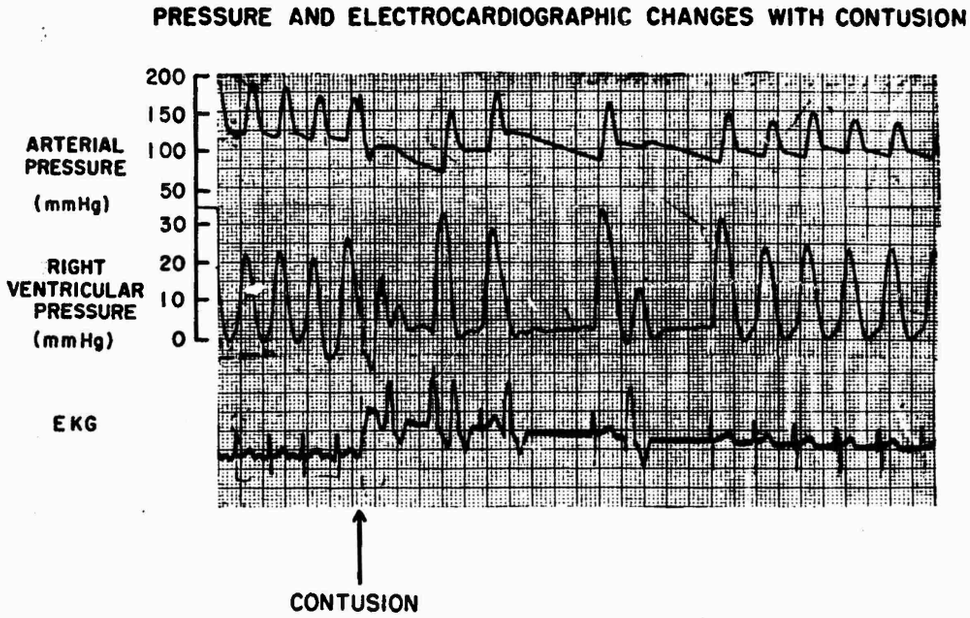

FIG. 8

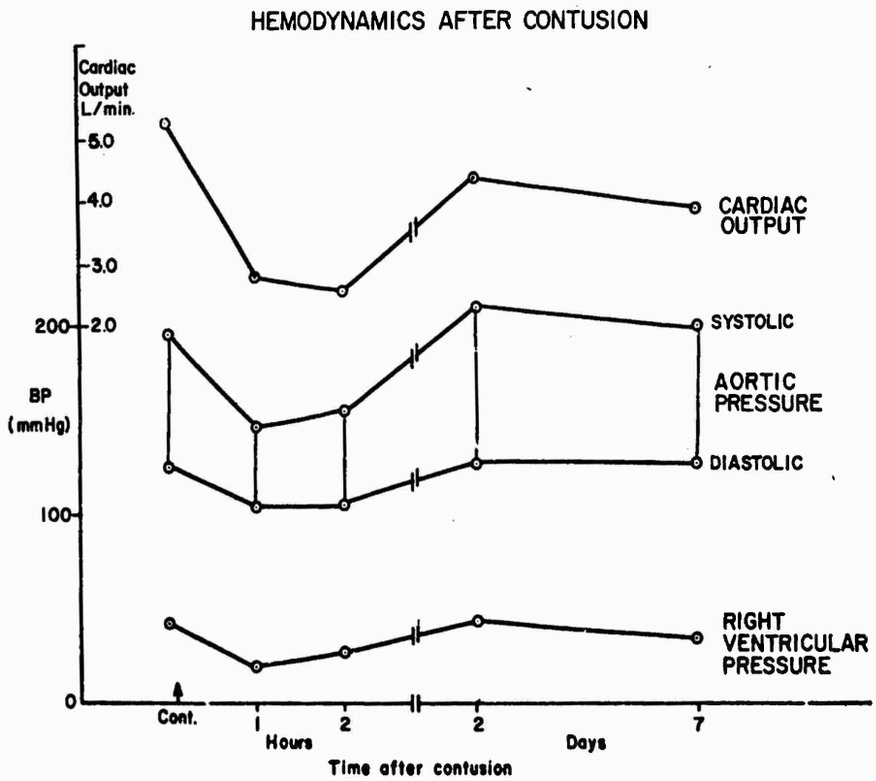

FIG. 9

have been shown to produce this effect (13). Even though each animal serves as its own control, variations in the degree of induced anesthesia clearly influence such factors as respiratory rate and tidal volume in a way that cannot be adequately controlled, and suggest caution in extrapolating these data to humans. However, radiologically and

pathologically the lesion produced is similar to that seen in human injury (1). The initial insult presumably results in instantaneous violent compression of the chest wall which crushes and tears lung tissue. This is most obvious directly under the site of external injury and where the lung is compressed against the vertebral column. Resultant bleeding into the airway obstructs bronchioles and alveoli, and aspiration of blood to uninjured and dependent areas of the lung compounds the amount of atelectasis. Continued perfusion of these nonventilated alveoli produces venous admixture and arterial hypoxemia which is most apparent when 100% oxygen is breathed. The physiologic shunt which develops under these circumstances amounts to more than 35% of the cardiac output. Comparable changes in blood gases and intrapulmonary shunting were produced by simple instillation of blood into one side of the Carlens tube.

Changes in respiratory rate and tidal and minute volumes following injury are partly reflex in nature and partly the result of the stimulus of hypoxemia. Anesthesia undoubtedly modified these responses, because while lower reflex pathways remain intact, there is less antalgic restriction of chest wall motion than is seen in awake humans following chest injury (4, 11). Increased respiratory rate, which always followed initial reflex apnea, resulted in quite adequate alveolar ventilation, since pCO_2 fell and there was a mild respiratory alkalosis. Others (12) have observed CO_2 retention, though this is not seen in humans (2, 11), and again suggests an effect of variation in the depth of anesthesia.

In this study, assisted ventilation usually decreased the amount of shunting both before and after contusion, but the differences are small and not statistically significant. Prior to contusion this is probably the result of reversing anesthetic effects, as Finley et al. (7) have shown. After contusion, a similar decrease in shunt was observed. Other experimental studies have shown dramatic benefits of assisted ventilation in the treatment of this pulmonary injury (12). Many authors (2, 3, 11), ourselves included, have also demonstrated the value of assisted ventilation following chest injury in man. The minimal effect seen here is probably due to the fact that we made no effort to remove the blood and mucus which often completely occluded the major right bronchus. In patients, it is the tracheostomy which makes thorough tracheal toilet possible and permits assisted ventilation to produce better alveolar aeration, as shown by Burford and Burbank (4) 25 years ago. It is pertinent that assisted ventilation did not produce adverse hemodynamic effects. The decrease in cardiac output was minimal over a wide range of tidal and minute volumes, confirming the clinical studies of Hedley-Whyte, Pontoppidan, and Morris (8).

The decrease in cardiac output after contusion is noteworthy, since arterial hypoxemia and shunting of blood in the pulmonary circuit are usually associated with increased cardiac output (6). The low cardiac output seen in this study has added significance, because it occurs when tissue demands for oxygen are greatest. Furthermore, in the presence of a large intrapulmonary shunt, low cardiac output will theoretically exaggerate arterial hypoxemia as a result of admixture of venous blood with especially low oxygen tension (10). In the trial group of small animals, the early fall in cardiac output after injury was progressive and resulted in a high mortality. When the larger animals were used, blood pressure changes were transient, although the decrease in cardiac output persisted. This impairment in cardiac function was presumably due to direct contusion of the myocardium, and would have been unrecognized without actual measurement of cardiac output. It suggests that low cardiac output may occur following comparable injury in the human, even when arterial blood pressure is normal. DeMuth (5) has emphasized the occurrence

of cardiac injury following tangential high-velocity missile wounds.

Hypovolemia resulting from hemorrhage and edema in the injured lung must also be considered a possible cause of decreased cardiac output. In the pilot group of small animals, blood pressure and cardiac output returned to normal after treatment with large volumes of lactated Ringer's solution, but the effect was transient and death often occurred. After approximately 500 ml of fluid had been given, and arterial and ventricular pressure were essentially normal, there was a sharp increase in radiographic density of the right side of the chest. At the same time, copious amounts of bloody, frothy "edema fluid" poured from the right side of the Carlens tube while the left side remained dry. Although an element of heart failure was undoubtedly present in this situation, the observation lends support to the clinical impression that "pulmonary edema" is more likely to occur in a lung which has had a previous injury (4).

SUMMARY

A convenient method for producing a closed chest injury in dogs is described. The lesion produced is similar to that following closed chest injury due to compression or high-velocity missile wounds in man. Immediately following injury there was reflex apnea, but subsequently increased respiratory rate and minute volume resulted in mild respiratory alkalosis. Continued perfusion of alveoli, occluded with blood at the site of injury, resulted in arterial hypoxemia due to venous admixture or physiologic intrapulmonary shunting of blood. The importance of blood aspirated to uninjured areas of the lung in compounding shunting and hypoxemia is emphasized. Failure to remove this blood and mucus from the airway by mechanical means probably accounts for the minimal beneficial effects of assisted ventilation.

A decrease in cardiac output was demonstrated after injury, and persisted after the return of blood pressure to normal. Diminished cardiac function, when demands for increased tissue blood flow were greatest, was probably due to the direct myocardial injury, although hypovolemia may have contributed. Infusion of balanced electrolyte solution restored blood pressure and cardiac output to normal, but was complicated by the development of "edema" of the injured lung. Barbiturate anesthesia produced significant changes in pulmonary function which modified the response to injury, and this must be recognized when extrapolating experimental data to the injured patient.

REFERENCES

1. Alfano GS, Hale HW Jr: Pulmonary contusion. *J Trauma* 5:647–656, 1965
2. Ambiavagar M, Robinson JS, Morrison IM, et al: Intermittent positive pressure ventilation in the treatment of severe crushing injuries of the chest. *Thorax* 21:359–366, 1966
3. Ashbaugh DG, Petty TL, Bigelow DB, et al: Continuous positive pressure breathing (CPPB) in adult respiratory distress syndrome. *J Thorac Cardiovasc Surg* 57:31–41, 1969
4. Burford TH, Burbank B: Traumatic wet lung. *J Thorac Surg* 14:415–424, 1945
5. DeMuth WE Jr: High velocity bullet wounds of the thorax. *Amer J Surg* 115:616–625, 1968
6. Doty DB, Moseley RV, Pruitt BA Jr: Hemodynamic consequences of respiratory insufficiency following trauma. *J. Thorac Cardiovasc Surg* 58:374–384, 1969
7. Finley TN, Lenfant C, Haab J, et al: Venous admixture in the pulmonary circulation of anesthetized dogs. *J Appl Physiol* 15:418–424, 1960
8. Hedley-Whyte J, Pontoppidan H, Morris MJ: The response of patients with respiratory failure and cardiopulmonary disease to different levels of constant volume ventilation. *J Clin Invest* 45:1543–1554, 1966
9. Hopkinson BR, Border JR, Schenk WG Jr: Experimental closed chest trauma. *J Thorac Cardiovasc Surg* 55:580–585, 1968
10. Kelman GR, Nunn JF, Prys-Roberts C, et al: The influence of cardiac output on arterial oxygenation: a theoretical study. *Brit J. Anaesth* 39:450–458, 1967
11. Moseley RV, Doty DB: Physiologic changes

following chest injury in combat casualties. *Surg Gynec Obstet* 129:233–242, 1969

12. NICHOLS RT, Pearce HJ, GREENFIELD LJ: Effects of experimental pulmonary contusion on respiratory exchange and lung mechanics. *Arch Surg* 96:723–729, 1968
13. PRIANO LL, TRABER DL, WILSON RD: Barbiturate anesthesia: an abnormal physiologic situation. *J Pharm Exp Therap* 165:126–135, 1969
14. SEVERINGHAUS JW: Oxyhemoglobin dissociation curve correction for temperature and pH variation in human blood. *J Appl Physiol* 12:485–486, 1958