AMRL-TR-66-234
AD0653526

PATHOLOGY OF OXYGEN TOXICITY IN FORTY MACACA MULATTA

FARREL R. ROBINSON, MAJOR, USAF, VC

DAVID T. HARPER, CAPTAIN, USAF, MC

HAROLD P. KAPLAN, CAPTAIN, USAF, MC

ANTHONY A. THOMAS, MD

MARCH 1967

20060711013

Distribution of this document is unlimited

STINFO COPY

AEROSPACE MEDICAL RESEARCH LABORATORIES
AEROSPACE MEDICAL DIVISION
AIR FORCE SYSTEMS COMMAND
WRIGHT-PATTERSON AIR FORCE BASE, OHIO

NOTICES

When US Government drawings, specifications, or other data are used for any purpose other than a definitely related Government procurement operation, the Government thereby incurs no responsibility nor any obligation whatsoever, and the fact that the Government may have formulated, furnished, or in any way supplied the said drawings, specifications, or other data, is not to be regarded by implication or otherwise, as in any manner licensing the holder or any other person or corporation, or conveying any rights or permission to manufacture, use, or sell any patented invention that may in any way be related thereto.

Requests for copies of this report should be directed to either of the addressees listed below, as applicable:

Federal Government agencies and their contractors registered with Defense Documentation Center (DDC):

DDC
Cameron Station
Alexandria, Virginia 22314

Non-DDC users (stock quantities are available for sale from):

Chief, Storage and Dissemination Section
Clearinghouse for Federal Scientific & Technical Information (CFSTI)
Sills Building
5285 Port Royal Road
Springfield, Virginia 22151

Organizations and individuals receiving reports via the Aerospace Medical Research Laboratories' automatic mailing lists should submit the addressograph plate stamp on the report envelope or refer to the code number when corresponding about change of address or cancellation.

Do not return this copy. Retain or destroy.

The experiments reported herein were conducted according to the "Principles of Laboratory Animal Care" established by the National Society for Medical Research.

700 - May 1967 - CO192 - 34-860

AMRL-TR-66-234

PATHOLOGY OF OXYGEN TOXICITY IN FORTY MACACA MULATTA

FARREL R. ROBINSON, MAJOR, USAF, VC

DAVID T. HARPER, CAPTAIN, USAF, MC

HAROLD P. KAPLAN, CAPTAIN, USAF, MC

ANTHONY A. THOMAS, MD

Distribution of this document is unlimited

Foreword

This work was performed under Project 6302 "Toxic Hazards of Propellants and Materials," Task 630206 "Toxicological Support," administered by the Pathology Branch, Toxic Hazards Division, Biomedical Laboratory, of the Aerospace Medical Research Laboratories, Wright-Patterson Air Force Base, Ohio. The work was initiated in May 1965 and completed in April 1966.

The assistance rendered by members of the Veterinary Medicine Division, Aerospace Medical Research Laboratories, is gratefully acknowledged.

This technical report has been reviewed and is approved.

WAYNE H. McCANDLESS
Technical Director
Biomedical Laboratory
Aerospace Medical Research Laboratories

Abstract

Forty monkeys *(Macaca mulatta)* were exposed to 99-100% oxygen at pressures from 600 to 760 mm Hg. The acute exudative pulmonary response was seen in only three exposed at 760mm Hg. The subacute proliferative pulmonary response was seen at all levels studied, the degree being directly related to time-dose exposures. In the high dose ranges clinical signs of illness were evident after 5-7 days exposure when the monkeys became listless and anoretic. By 14 days they were quite lethargic and had assumed a huddled position. Grossly, the heavy lungs had a gray, bloodless appearance. Microscopically, there was extreme proliferation of the interstitium and alveolar epithelium. None of the monkeys that were exposed at 600 mm Hg died, although mild focal proliferative changes were seen. After 31 days postexposure, these changes appeared as focal areas of atelectasis with mild septal fibrosis.

SECTION I.
Introduction

Classical lesions in rats, mice, and dogs dying of acute oxygen toxicity include copious amounts of clear, serous pleural fluid and dark purple lungs, which have a rubbery consistency and sink in fixing fluid (ref 1, 2, 4, 11, 13). Pathology of subacute effects is not well documented. Friedrich and Grayzel (ref 5) reported pulmonary lesions in rhesus monkeys that had survived from 6 to 18 days in 90-95% oxygen at one atmosphere in a modified oxygen tent. Microscopically the lungs showed congestion, edema, small foci of pneumonia, and small areas of emphysema. Cook and Leon (ref 3), working with squirrel monkeys, reported moderate lung damage in two that died after 15 days of exposure at 622 mm Hg of oxygen tension. The pulmonary lesions were not described, but may have been associated with daily returns to ambient conditions for feeding and cleaning. Weir *et al* (ref 13) reported pulmonary lesions, comparable to those described herein as the early proliferative type, in two young adult, male Sooty Mangebey monkeys that had been exposed to 95-99% oxygen at ambient pressure until death in 6 and 9 days. These two monkeys had gray, glistening lungs which microscopically had alveolar wall thickening and alveolar cells with swollen, vesicular nuclei. This difference in response between monkeys and lower mammalian forms was also noted in our preliminary experiments and provided the stimulus to investigate oxygen toxicity more extensively in monkeys.

SECTION II.
Materials and Methods

A series of three experiments was designed to delineate the pathological response of the monkey *(Macaca mulatta)* to high concentrations of oxygen at 600, 650, 695, 720, and 760 mm Hg pressure.

All monkeys were *M. mulatta* that had been stabilized for at least 90 days before the experiment was started, and had shown no response to three successive monthly intrapalpebral tuberculin tests. Number of monkeys, sex, and weight data are summarized in table I.

TABLE I.

SUMMARY OF DATA ON MONKEYS USED IN OXYGEN EXPERIMENTS

Experiment No.	*No. of Monkeys Male/Female*	*Average Weight (kg)*	*Weight Range (kg)*
1	11/9	4.2	2.7 - 5.4
2	3/2	2.3	2.0 - 2.7
3	11/4	5.0	4.1 - 6.6
Controls	6/6	3.9	2.7 - 5.7

All three experiments were conducted in the Toxic Hazards Research Unit (THRU) of the Aerospace Medical Research Laboratories at Wright-Patterson AFB, Ohio. The Thomas domes in the THRU are unique exposure chambers, which have been described in detail in reference 12. In brief, they are dynamic flow experimental altitude chambers in which the environmental conditions are automatically controlled to narrow ranges (table II). Pressures are maintained at the prescribed level and average oxygen concentration is maintained between 99% and 100% at average flow rates between 18 and 23.4 cu ft/ min (about 500-650 liters/min). Temperature remains at about 72F (22.2C) and the average relative humidity at about 50% with only temporary fluctuations, usually during the entry and cleaning procedures. When dome pressure was maintained at 760 mm Hg, pressure was reduced to 720 mm Hg when the dome was entered and it remained at that level for about 30 minutes. Entries were made through the airlock daily to care for the monkeys and as often as required to remove dead animals. The monkeys were fed Purina Monkey Chow and water ad libitum.

TABLE II.

MEANS AND STANDARD DEVIATIONS OF MONITORED ENVIRONMENTAL CONDITIONS FOR ALL EXPERIMENTS AT PRESSURES SHOWN

Pressure (mm Hg)	*Flow (cu ft/min)*	*Temperature (F)*	*Relative Humidity (%)*	*Oxygen (%)*	*Carbon Dioxide (%)*
600*	19.6	70.9	51	99.9	0.10
±0	±0.7	±0.4	±10	±0.1	±0.08
650	20.3	72.7	52	99.8	0.20
±0	±1.0	±2.0	±11	±0.2	±0.16
695	23.4	71.7	51	99.7	0.30
±5	±0.5	±2.3	±11	±0.2	±0.17
720	20.7	72.8	53	99.8	0.20
±0	±1.3	±1.4	±18	±0.2	±0.16
760	18.0	72.1	59	99.9	0.10
±6	±0.1	±1.4	±10	±0.1	±0.08

*Means and standard deviations calculated from 48 readings per day. Pressure changes of less than 1 mm Hg were not used in calculating the standard deviations.

All monkeys were placed in a dome having an ambient air flow of 18 cu ft/min on the day before the start of the experiment. On the first day of the experiment the dome was purged with 100% oxygen until the oxygen concentration reached 98% at which time the total pressure was adjusted to the prescribed level.

In experiment 1 (Exp. 1), five groups of four monkeys each were exposed to 99-100% oxygen environments at pressures of 600, 650, 695, 720, and 760 mm Hg to induce lesions and to determine the influence of pressure on mortality (table III). Two monkeys that survived a 15-day exposure at 600 mm Hg and one that survived a 16-day exposure at 650 mm Hg were taken to 258 mm Hg (99-100% oxygen) for 2 and 4 days, respectively. They were then returned to ambient conditions for 29- and 44-day observation periods, respectively.

TABLE III.

SUMMARY OF RESULTS ON EXPERIMENT ONE

(Monkeys were exposed to 99-100% oxygen at pressures shown.)

Pressure (mm Hg)	Sex	Days Exposed/ Postexposure	Killed or Died	Weight Change (kg)	Lung Weight*	Type of Lesion† Acute	Sub-acute	Chronic	Terminal Exud-Hem‡
600	F	15/0	K	–0.68	NR		1+		
	M	15/0	K	–1.36	NR		1+		
	M	15/31	K	0	NR			2+	
	F	15/31	K	–0.20	NR			2+	
650	M	14/0	D	0	NR		2+		3+
	M	16/0	D	–0.90	NR		2+		
	M	16/0	K	–0.91	NR		2+		
	M	16/48	K	+0.12	NR			2+	
695	M	12/0	D	–1.13	NR		3+		4+
	F	14/0	K	–1.19	NR		3+		4+
	F	14/0	K	–1.36	NR		3+		4+
	M	14/0	K	–1.13	NR		3+		4+
720	M	16/0	K	–1.81	2.38		4+		
	F	16/0	K	–0.91	2.67		4+		
	F	16/0	K	–0.91	2.51		4+		
	F	16/0	K	–1.13	3.39		4+		
760	F	3/0	D	+0.02	NR	4+			
	M	4/0	D	0	NR	4+			
	F	10/0	D	–0.58	2.23		4+		
	M	14/0	K	–0.34	2.48		4+		

* Lung weight as per cent of body weight.
† 1+, 2+, 3+, and 4+ indicate increasing degrees of severity.
‡ Terminal exudation and hemorrhage.
NR Not recorded.

In experiment 2 (Exp. 2), five monkeys were exposed to a 99-100% oxygen environment at an atmospheric pressure of 760 mm Hg to study the development of pulmonary lesions over the initial 5-day period (table IV).

TABLE IV.

SUMMARY OF RESULTS ON EXPERIMENTS TWO AND THREE

(Monkeys were exposed to 99-100% oxygen at 760 mm Hg pressure for number of days shown.)

Sex	Days Exposure	Postexposure Period	Killed or Died	Lung Weight*	Type of Lesion† Acute	Sub-acute	Chronic	Terminal Exud-Hem‡
				Experiment Two				
M	1	0	K	0.67	NSL			
F	2	0	K	0.71	1+			
M	3	0	K	1.24	2+			
F	4	0	K	1.61	1+			
M	5	0	K	1.70	3+	1+		
				Experiment Three				
F	1	49 days	K	NR			NSL	
M		50 days	K	0.70			NSL	
M	2	64 hours	D	1.16	2+			2+
M		48 days	K	NR			NSL	
M	3	77 hours	D	1.29	2+			1+
F		48 days	K	1.04			NSL	
M	4	1 hour	D	1.92	2+			4+
M		7 hours	D	NR	2+			3+
M	5	1 hour	D	2.51	2+			2+
M		42 days	K	NR			2+	
M	6	11 hours	D	3.26	3+			2+
F		48 hours	D	1.46	1+	1+		3+
M	7	6 hours	D	2.19	2+	1+		2+
F		1 hour	D	2.29	3+	1+		1+
M	3	None (Died in Dome)	D	3.14	4+			

* Lung weight as per cent of body weight.
† 1+, 2+, 3+, and 4+ indicate increasing degrees of severity.
‡ Terminal exudation and hemorrhage.
NSL No significant lesions.
NR Not recorded.

All but six of the monkeys surviving experiments 1 and 2 were killed with an intravenous barbiturate anesthetic in the dome in the same environment in which they had been exposed. The three held for observation in air as mentioned above and the three monkeys surviving the 695 mm Hg exposure were brought to the ambient environment before being killed in the same manner.

In experiment 3 (Exp. 3), 15 monkeys were exposed to a 99-100% oxygen environment at 760 mm Hg for periods up to 7 days (table IV). This study was designed to provide tissue for electron microscopy (EM) studies, the results of which will be reported later. Light microscopy changes are reported here.

Monkeys to be biopsied for EM studies were placed under intravenous barbiturate anesthesia and a laparotomy performed to facilitate biopsy of the kidney and liver with Menghini needles. Nine monkeys died following exposure and initial surgery over a postexposure time period ranging from less than 1 hour up to 77 hours. The 15th monkey in this series died in the dome after 64 hours of exposure. The five monkeys that survived the initial postexposure period and surgery were held at ambient conditions for observation periods ranging from 42 to 50 days. Following observation they were again placed under surgical anesthesia, and electron microscopy samples were taken before they were killed with an overdose of the barbiturate.

Twelve control monkeys were housed at ambient pressures and were handled in the same manner as the others except for exposure to increased oxygen levels.

Necropsy examinations were made on all monkeys as soon after death as possible and never longer than 4 hours postmortem. Lung weights were taken on monkeys indicated in tables III and IV. Tissues from all organ systems were preserved in neutral buffered formalin, embedded in paraffin, and sectioned at 5μ. A hematoxylin and eosin staining procedure was used routinely. Masson's trichrome and Wilder's reticulum staining procedures were used to demonstrate connective tissue elements. Selected lungs were perfused intratracheally with buffered formalin.

SECTION III.
Results

The responses of these monkeys to high concentrations of oxygen were conveniently divided into the acute exudative type and subacute proliferative type. Chronic changes studied in this series were limited to histopathological findings on monkeys surviving low time-dose exposures and maintained under ambient conditions for observation periods up to 50 days before necropsy.

CLINICAL OBSERVATIONS

Acute Response

Early signs of respiratory distress were seen within 48 to 72 hours in those monkeys exposed to high concentrations of oxygen (600-760 mm Hg). They maintained an upright position in their cages and became progressively apprehensive. They remained alert when respiratory effort became labored as reflected by abdominal breathing. Two Exp. 1 and one Exp. 3 monkeys exposed at 760 mm Hg died in the dome following this acute syndrome. Terminally, serosanguinous and occasionally foamy exudate dripped from the nares and a limited amount of coughing often

produced a similar exudate. The monkeys then became comatose, fell over to a lateral decubital position, and soon died.

Subacute Response

Monkeys exposed to a sublethal time-dose exposure often exhibited various degrees of acute respiratory distress but recovered to develop signs associated with the subacute proliferative lesions seen postmortem. These subacute signs became evident after 5-7 days when the monkeys became progressively listless and anoretic. They lost weight, becoming emaciated and dehydrated prior to death. Terminally, they were quite lethargic, assumed a huddled position, which could be described as a "fetal" posture, and faced into the darkest corner of the cage. They became comatose and often died in this position, although some fell into a lateral decubital position before death. Respiration became depressed and there was no terminal respiratory effort similar to that seen in monkeys dying acutely.

Clinical signs in monkeys removed from the domes varied, depending on the time-dose exposure and the individual monkey's response. Exp. 3 monkeys were given "oxygen therapy" (50% oxygen at ambient pressure), after removal from the dome, so that biopsies for electron microscopy could be obtained from living animals. Even so, there were three deaths in one hour or less following exposure. These monkeys and others in Exp. 3 dying within 77 hours exhibited signs similar to those described for the acute syndrome. Exp. 1 and 3 monkeys that lived from 31 to 50 days had variable degrees of respiratory distress in the first to third days after initial exposure before their recovery became apparent. They appeared to be clinically healthy monkeys at the end of the postexposure holding period.

GROSS PATHOLOGY

Acute Response

Significant gross lesions in the three Exp. 1 and 3 monkeys that died in the dome following the acute syndrome were limited to the lungs. The lungs were quite heavy with serous fluid and blood resulting in varying shades of red and reddish-blue. Clear serous fluid often ran from the trachea and from the cut surface when slight pressure was applied. The lungs tended to sink in the formalin fixative. A marked increase of pleural fluid was limited to one monkey in which the lung made up 3.14% of the body weight. Experiment 3 monkeys that died within 77 hours after the biopsy procedures had similar gross lesions, except that acute widespread hemorrhage and alveolar emphysema were more evident.

Developing gross lesions were seen in the lungs of four of five Exp. 2 monkeys. Lungs of monkeys killed from days 2 to 5 showed progressively larger areas of patchy atelectasis and edema with the degree of involvement being moderate on day 5. Lung weight data (table IV) indicate a progressive increase in lung weight over the 5-day period.

Subacute Response

Significant gross lesions in the monkeys that died or were killed following the subacute syndrome were also limited to the lungs. The lungs had an almost dry surface, were nearly bloodless, and were tan or yellowish-gray. They had a firm texture and sank in the formalin fixative. This type of gross pulmonary change was marked in four Exp. 1 monkeys exposed at 720 mm Hg pressure, and also in one surviving the 14-day exposure at 760 mm and one dying after 10 days. Excessive amounts of pleural and pericardial fluid were noted in one monkey exposed at 720

mm Hg. Lung weights ranged from 2.23% to 3.39% of the body weights. The lung weights of the 12 control monkeys did not exceed 1.0% of the body weights (mean 0.76%, range 0.64-0.94%).

MICROSCOPIC PATHOLOGY

Microscopic lesions associated with the presence of lung mites *(Pneumonyssus simicola)* were seen in all lungs. Every effort was made to exclude these lesions from those to be described as a result of exposure to high concentrations of oxygen. The acute exudative and the subacute proliferative responses to high concentrations of oxygen are described separately. Variations and combinations of these two types are related to exposure conditions in tables III and IV.

Acute Response

The acute exudative response was best demonstrated in two Exp. 1 monkeys and one Exp. 3 monkey exposed to oxygen at 760 mm Hg and dying within 3-4 days. These lesions consisted of massive alveolar edema, patchy emphysema, and mild scattered hemorrhage. Large zones of fresh edema were coexistent in central portions of the lobes with resolving alveolar fibrinous exudate, containing small numbers of neutrophils and erythrocytes and occasional mononuclear macrophages. Small neutrophilic aggregates, occupying from two to four alveoli, were scattered through lung sections of the Exp. 3 monkey. The fibrinocellular exudate in peripheral emphysematous portions of the lobes was resolving. A mild interstitial inflammatory exudate consisted of scant edema, several neutrophils and scattered lymphocytes. There was no evidence of proliferative changes in the interstitium or epithelium and no bronchiolar inflammation.

The amount of alveolar edema varied considerably in the lungs of Exp. 3 monkeys dying after 4 to 7 days exposure. Large zones of fresh edema were often superimposed on resolving alveolar exudate. This exudate usually appeared as fibrin which was layered and adhered to the alveolar walls and lower air passages occasionally taking on the appearance of a hyaline membrane (fig. 1 and 2). Mononuclear alveolar macrophages were usually present in alveoli containing resolving fibrinocellular exudate along with neutrophils that appeared first in a random fashion and later in small focal aggregates in contiguous alveoli.

Other microscopic observations consisted of mild to moderate congestion of the liver, spleen, adrenal, and in one monkey, the brain. Moderate focal degenerative changes were seen in the pancreas of one monkey.

Subacute Response

Microscopic lesions of the proliferative type were seen in monkeys following the subacute clinical syndrome. These lesions consisted of variable amounts of proliferation of the pulmonary interstitium and hypertrophy and still later hyperplasia of the alveolar lining epithelium. This response was first seen as early at the 5th day in Exp. 2 and the 6th day in Exp. 3. It consisted of mild hypertrophy of the alveolar lining cells and mild edema with fibrillar material in the interstitium along with moderate numbers of immature lymphocytes, and a small number of septal cells. In the alveoli there was often resolving exudate containing fibrin with entrapped neutrophils, mononuclear phagocytic cells, and an occasional desquamated alveolar cell. In a few monkeys, there were layers of fibrin lining the alveoli and rarely, hyaline membranes. Proliferative and hypertrophic changes that ranged from mild to moderate tended to be focal in distribution at the lower dose levels in Exp. 1 animals (fig. 3).

The maximum proliferative response was seen in those monkeys surviving the exposure at 720 and 760 mm Hg in Exp. 1. The interstitium of the septae was greatly thickened due to col-

lagenous as well as reticular fibers (fig. 4 and 5). Moderate numbers of small lymphocytes and fibroblasts also contributed to the thickness of the septae (fig. 6 and 7). Only modest increases in vascularity accompanied the proliferative changes in the septae, and congestion or hyperemia was not evident in these lungs. Alveolar lining cells were markedly enlarged and the lining itself hyperplastic, often appearing to be several cells thick (fig. 8). Desquamated alveolar lining cells appeared in the alveoli in large numbers with a few mononuclear phagocytes. Epithelial hyperplasia and increased goblet cell activity was evident in the lower respiratory passages, and resolving fibrinocellular exudate was often seen in the bronchioles.

Other microscopic lesions included mild to moderate focal chronic myocarditis, primarily in those monkeys exposed at 600 and 650 mm Hg where three of four and two of four, respectively, had these lesions. The latter two died after exposures of 14 and 16 days. One case of moderate focal acute myocarditis was seen in the Exp. 3 monkey that was exposed for 6 days and died 2 days later. Mild focal subendocardial hemorrhages occurred in a monkey that was exposed for 3 days and died 3 days later.

Congestion of the liver was seen in many monkeys as well as occasional mild cases of focal hepatitis and pericholangitis. Fatty changes in the liver were recorded from three monkeys; in the one that died after 12 days exposure at 695 mm Hg, this lesion was severe and diffusely distributed. Mild to moderate chronic pyelonephritis or glomerulonephritis, with accompanying tubular changes in some, was seen in about 25% of the monkeys. Congestion at the corticomedullary junction of the kidney was recorded from about 10% of the monkeys as was a similar incidence of adrenal congestion. Chronic cystitis was seen in two monkeys (5%). Mild to moderate degenerative or fibrotic changes of the pancreas were seen in 10% of the monkeys.

Chronic Response

Mild chronic changes in the lungs were seen in those monkeys surviving for several weeks after initial exposure up to 5 days at 760 mm Hg and 15 or 17 days at 600 and 650 mm Hg. These changes consisted of small focal areas of atelectasis where the interstitium appeared to have more collagenous fibers than the surrounding septae of alveoli that were mildly emphysematous (fig. 9).

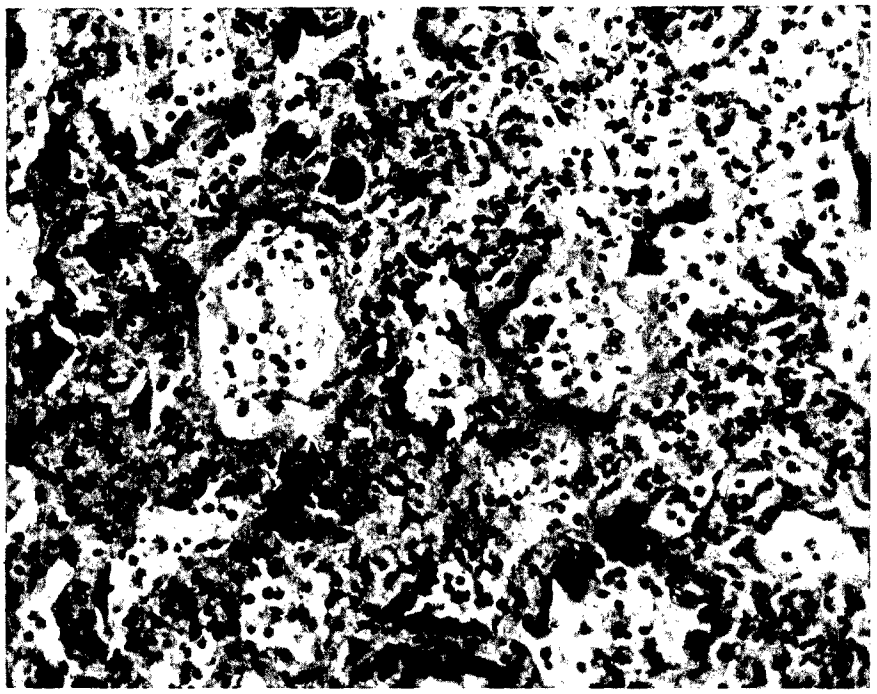

Figure 1. Layering of fibrin in alveoli and interstitial inflammation in the lung of a monkey exposed to oxygen at 760 mm Hg for 6 days and surviving for 11 days following surgical biopsy. (H & E stain — x 125)

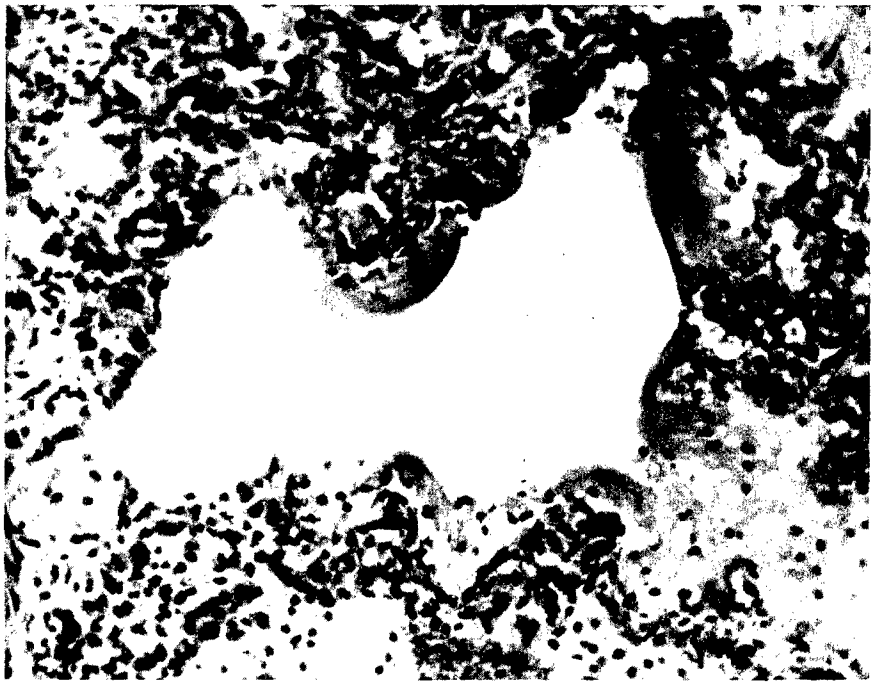

Figure 2. Accumulation of fibrin in a lower air passage appearing as hyaline in some parts in the lung of a monkey exposed to oxygen at 760 mm Hg for 6 days and surviving for 11 hours after surgical biopsy. (H & E stain — x 125)

Figure 3. Focal areas of proliferation and interstitial inflammation in the lung of a monkey surviving 16 days exposure to oxygen at 650 mm Hg. (H & E stain — x 25)

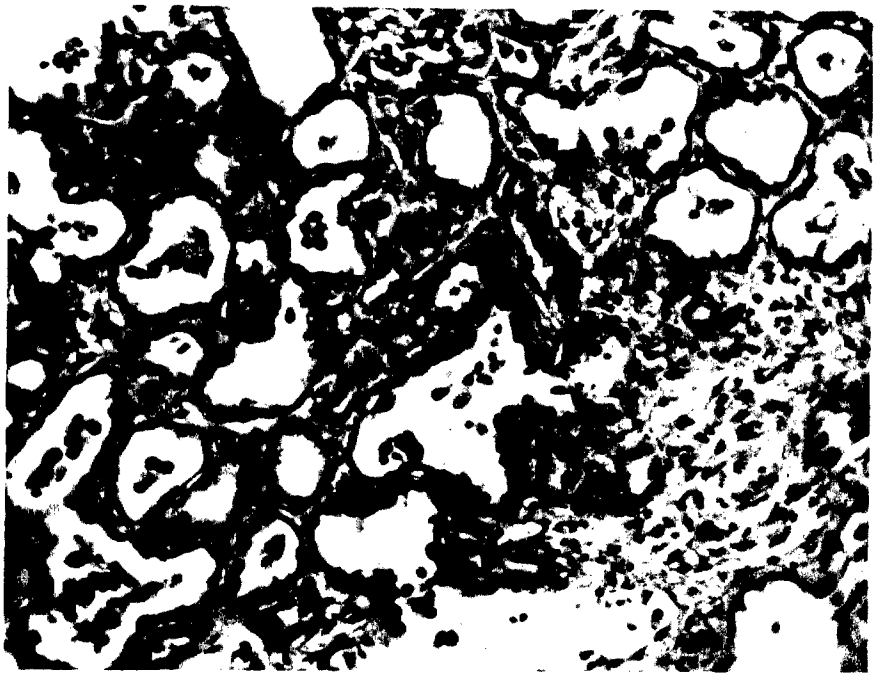

Figure 4. Marked thickening of the septae and hyperplasia of the alveolar lining cells in the perfused lung of a monkey that died after 10 days exposure to oxygen at 760 mm Hg. (H & E stain — x 125)

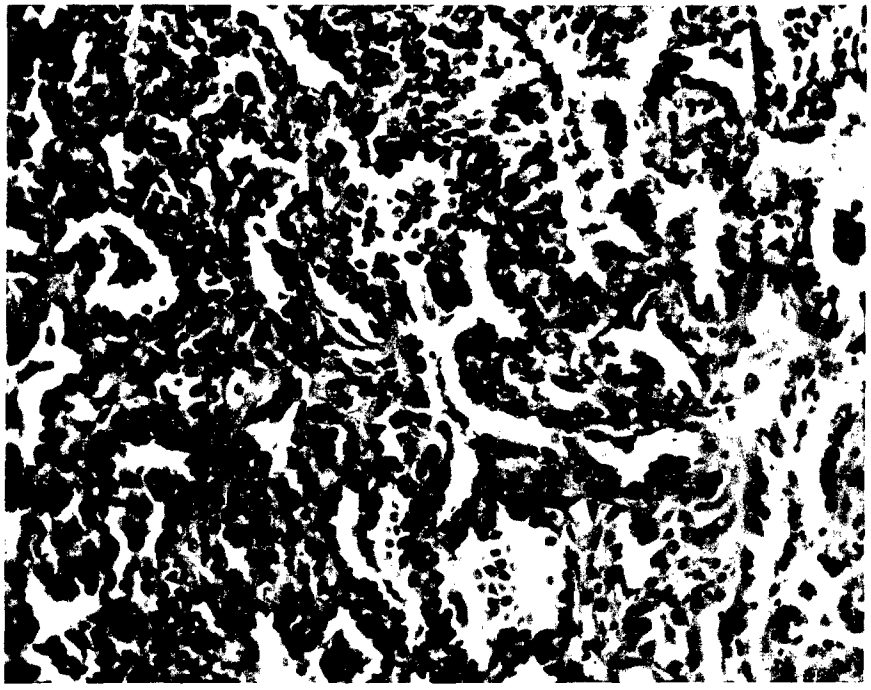

Figure 5. Marked thickening of the septae and hyperplasia of the alveolar lining cells in the unperfused lung of a monkey that survived 14 days exposure to oxygen at 760 mm Hg. (H & E stain — x 125)

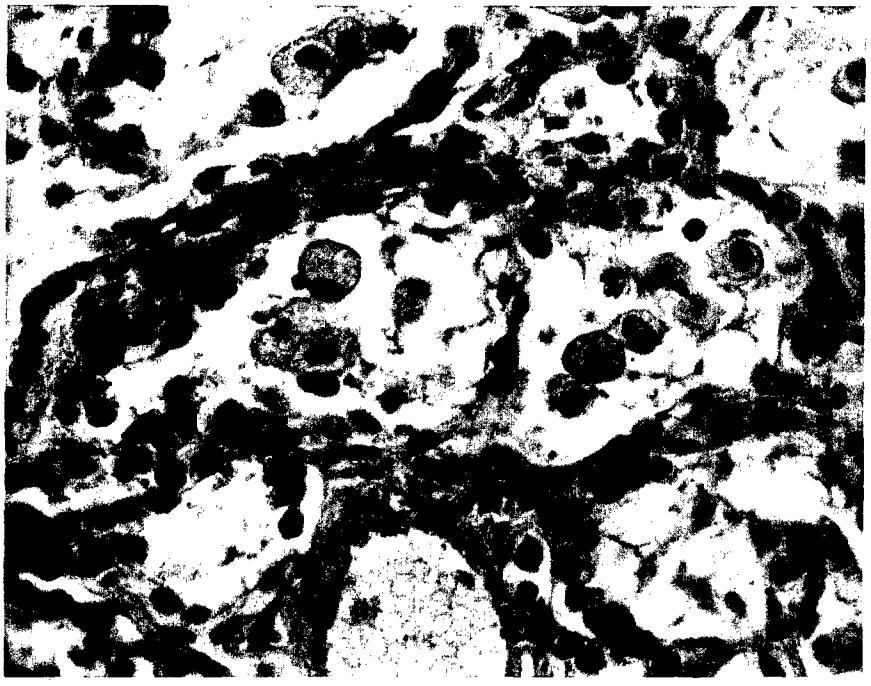

Figure 6. Thickened interstitium with inflammatory cells and collagenous tissue, alveolar exudate and hypertrophic lining cells in the lung of a monkey surviving a 16-day exposure to oxygen at 720 mm Hg. (H & E stain — x 400)

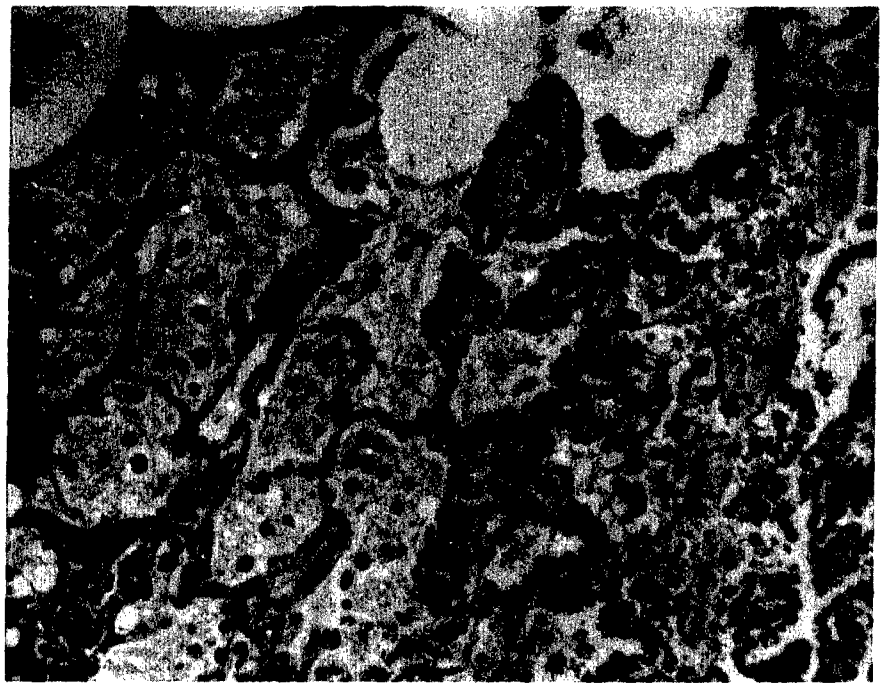

Figure 7. Focal interstitial inflammation and alveolar fibrinocellular exudate in the lung of a monkey surviving a 16-day exposure to oxygen at 720 mm Hg. (H & E stain — x 125)

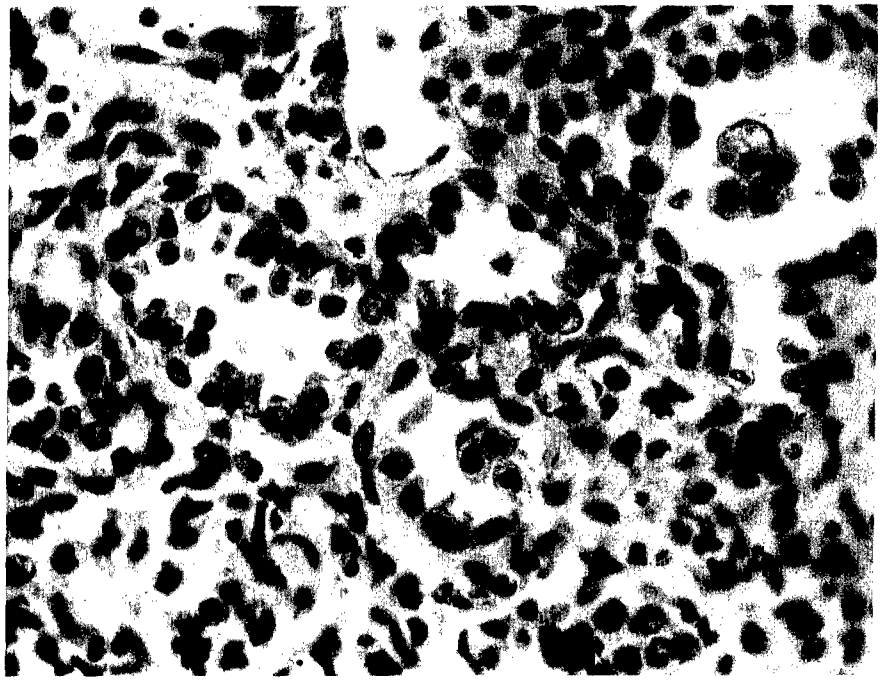

Figure 8. Hypertrophy of alveolar lining cells in the lung of a monkey surviving exposure to oxygen at 720 mm Hg for 16 days. (H & E stain — x 400)

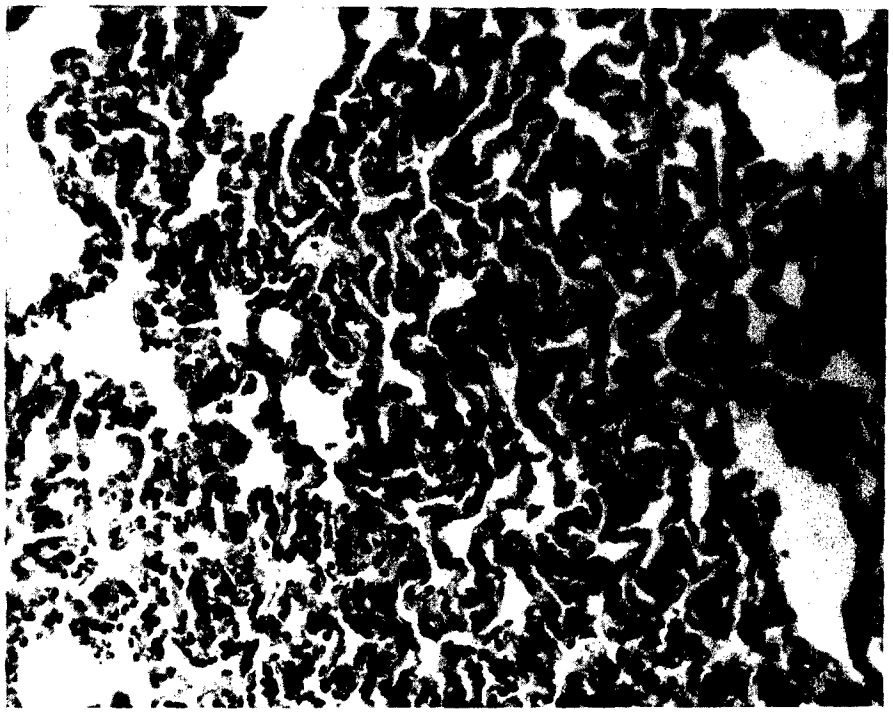

Figure 9. Focal atelectasis and mild fibrosis in the lung of a monkey that survived 16 days of exposure to oxygen at 650 mm Hg and was held 48 days before examination. (H & E stain — x 125)

SECTION IV.
Discussion

Acute exudation and hemorrhage as seen in the lungs of lower mammals, i.e., dogs, rats, and mice, has been accepted as the classical pulmonary response to concentrations of oxygen near 760 mm Hg. There has been little proof that subhuman primates would react the same as lower mammals. Therefore, investigators have been rightfully hesitant in extrapolating this information to man.

Our results using *M. mulatta* show two distinct and characteristic pulmonary lesions, which we have termed the acute exudative and the subacute proliferative responses. The acute exudative response was not often seen in our monkeys but was comparable in general to the acute pulmonary exudation and hemorrhage induced by high concentrations of oxygen in lower mammals.

The subacute proliferative pulmonary lesions that were predominant in the lungs in our monkeys developed in the following chronology. At high rates of exposure, there was at first a mild interstitial pneumonitis that developed in the first 48 hours of exposure. Fluid transudation into alveoli progressed to fill most of the centrally located alveoli around terminal bronchioles at which time death may have occurred from anoxia.

At slightly lower doses of exposure and in those monkeys that could tolerate the higher levels of oxygen, there was an endpoint to the degree and extent of alveolar edema. Fibrin formed in the alveoli and resolution of the alveolar fibrinocellular exudate began. Mononuclear macro-

phages, lymphocytes, and occasional alveolar lining cells took part in the resolving process. Neutrophils formed microabscesses in the alveoli of some lungs. If there was a concurrent bacterial infection in the nutrient rich alveolar fluid, neutrophils were more numerous. Starting on day 5 or 6, the alveolar lining cells became noticeably large and the interstitial cell population increased with the appearance of young fibroblasts and septal cells having large vesicular nuclei. By day 10 alveolar lining cells were hyperplastic and thrown up into folds. Desquamated alveolar lining cells became more numerous in the resolving alveolar exudate. The interstitium became quite thick and fibroblastic activity was more noticeable. About day 14-16 the interstitial reactive cells were assuming a more mature character in that the septal cells were smaller and collagenous fibers more numerous. Lymphocytes were of the small type.

In the lungs exposed to lesser doses, the proliferative lesions tended to be focal rather than uniform. In monkeys that survived for several weeks after exposure, the focal areas of proliferation became atelectatic and collagen was prominent in the septae of the collapsed alveoli.

Most of the microscopic lesions in other than the lungs were of questionable relevance to oxygen toxicity. These lesions were sporadically distributed and were either secondary to the pulmonary lesions or, more probably, the result of preexisting spontaneous disease. The only possible exception to this was the occurrence of chronic myocarditis in the monkeys exposed at 600 and 650 mm Hg. Since there was no increase in incidence or severity with increases in exposure pressure, their significance is unresolved. This is true, particularly, since similar lesions have been seen sporadically in monkeys in other experiments.

The innate ability of each individual monkey to adapt to the high concentrations of oxygen may be an extremely important factor in its survival and in the pathogenesis of these different lesions. The acute exudative pulmonary lesion developed in only two of four Exp. 1 monkeys exposed at 760 mm Hg while the other two developed the subacute proliferative lesion. The four monkeys exposed at 720 mm Hg exhibited the most uniform response of all groups studied because all survived the experimental period and all had maximal proliferative pulmonary lesions.

One monkey exposed at 695 mm Hg and two at 650 mm Hg died between days 12 and 16 of exposure. However, all showed some degree of proliferation of pulmonary tissue and two of three had marked amounts of pulmonary edema, which probably occurred as a terminal event.

There is reason to believe that age may influence survivability. After exposure to 760 mm Hg for up to 5 days, none of the five younger monkeys in Exp. 2 (2.0-2.7 kg) died while three of nineteen older monkeys in Exp. 1 and 3 (2.7-6.6 kg) died.

Appreciable weight losses occurred only if the monkeys lived for 10 days or more in the high oxygen concentrations. In Exp. 1 the greatest weight loss was in the monkeys exposed at 695 mm Hg and the next greatest was at 720 mm Hg.

Increases in lung weight must be qualifed to differentiate fluid and cells. Increases in lung weight up to 3.39% of the body weight was recorded from one animal (Exp. 1) with a typical proliferative response. The lungs of one monkey (Exp. 3) dying in the acute stage where edema and hemorrhage were predominant made up 3.14% of his body weight. Another monkey's lungs (Exp. 3) were 3.26% of his body weight; this monkey had been exposed 6 days and lived 11 hours after surgery and had both severe pulmonary edema and early proliferative changes.

In Exp. 2 where the smallest monkeys were used, there was a uniform increase in lung weight over the 5-day period. This increase due to pulmonary edema rather than proliferation of cells was also evident in those monkeys dying within hours after exposure in Exp. 3.

Several factors in Exp. 3 influenced mortality and the production of lesions. Effectiveness of oxygen therapy after the monkeys were removed from the dome, variation in the lethality of the intravenous barbiturate anesthesia, trauma of surgery and biopsy, and subsequent problems associated with recovery present a formidable array of variables upon which to base a judgment involving oxygen toxicity. Even so, increasing the length of exposure correlated in general with increasing mortality and decreasing survival time following surgery and biopsy. Both monkeys exposed for 1 day survived exposure and surgery, while none exposed for more than 5 days survived for more than 2 postsurgical days. Removal of these monkeys after 48 hours in their 99-100% oxygen environment caused respiratory distress that increased in severity with increase in exposure time. Oxygen therapy somewhat alleviated the signs of respiratory distress, but apparently did not provide adequate enrichment for prolonged survival. As respiratory distress increased so did the amount of alveolar edema.

Mild atelectatic and fibrotic changes were the only indications of residual effects seen in the lungs of those monkeys surviving the exposure in Exp. 1 and 3 and kept alive for several weeks. This indicates a reasonable chance for survival of *M. mulatta* after exposure to 99-100% oxygen to as high an atmospheric pressure as 600 mm Hg for 15 days, although there may be subsequent mild focal septal fibrosis.

Some of the pulmonary lesions seen in man that are related by way of possible etiology (oxygen) or morphology have a direct bearing on the lesions produced in these experiments.

Pratt (ref 10), in a study of autopsied human patients who had received oxygen therapy, concluded that patients receiving oxygen inhalation for as little as 2 days had pulmonary alterations consisting of capillary congestion and proliferation. He stated further that diffuse fibrosis had been encountered after continuous oxygen inhalation for 2 weeks. Fuson *et al.* (ref 6) reported a fatal human case of pulmonary oxygen toxicity arising as a result of hyperbaric oxygen therapy. In addition to the lesions referable to an anerobic infection, there were pulmonary lesions including intraalveolar hemorrhage, fluid transudation, and intraalveolar fibrinoid or hyaline membranes. These lesions are compatible with lesions seen in our monkeys exposed to 99-100% oxygen at 760 mm Hg pressure.

Two of the interstitial pneumonias of man are of particular morphological interest. Desquamative interstitial pneumonia (DIP) of man was recently reported by Liebow (ref 9) with additional cases reported by Gaensler, *et al.* (ref 7). The lesions of DIP are characterized by massive proliferation and desquamation of large alveolar cells. There is slight thickening of the walls of the distal air spaces, no necrosis, and minimal loss of tissue. The subacute proliferative lesions in the lungs of our monkeys are similar to those in DIP in that there is a pronounced hyperplasia of the alveolar lining cells and subsequent desquamation and no necrosis. The lesions are dissimilar in that there is a marked proliferation of the interstitium in the monkey lungs and an actual increase in tissue.

Acute diffuse interstitial fibrosis reported by Hamman and Rich (ref 8) is a pulmonary disease with a rapid clinical progression to death within a few months. In the early stage there is an acute exudative pneumonitis in which hyaline membranes are prominent; later fibroblastic invasion and proliferation result in fibrosis. To date there has been no experimental model for the study of the Hamman-Rich syndrome. The clinical syndrome and the subacute proliferative lesion produced in our monkeys breathing 99-100% oxygen at 720 mm Hg pressure may serve as a reasonable model for the study of acute diffuse interstitial fibrosis.

References

1. Bean, J. W.: Effects of Oxygen at Increased Pressure. *Physiol. Rev.,* 25:1, 1945.
2. Bean, J. W., and Smith, C. W.: Hypophyseal and Adrenocortical Factors in Pulmonary Damage Induced by Oxygen at Atmospheric Pressure. *Amer. J. Physiol.,* 172:169, 1953.
3. Cook, S. F., and Leon, H. F.: *Survival of C-57 Mice and Squirrel Monkeys in High and Low Pressures of Oxygen.* AFMDC TR 60-21, Air Force Missile Development Center, Holloman Air Force Base, New Mexico, 1960.
4. Felig, P.: Oxygen Toxicity: Ultrastructural and Metabolic Aspects. *Aerospace Med.,* 36:658, 1965.
5. Friedrich, M., and Grayzel, D. M.: High Resistance of Rhesus Monkeys to 90 Plus Per Cent Oxygen. *Proc. Soc. Exp. Biol. Med.,* 56:204, 1944.
6. Fuson, R. L., Saltzman, H. A., Smith, W. W., Whalen, R. E., Osterhout, S., and Parker, R. T.: Clinical Hyperbaric Oxygenation with Severe Oxygen Toxicity. *New Eng. J. Med.,* 273:415. 1965.
7. Gaensler, E. A., Goff, Anne M., and Prowse, C. M.: Desquamative Interstitial Pneumonia. *New Eng. J. Med.,* 274:113, 1966.
8. Hamman, L., and Rich, A. R.: Acute Diffuse Interstitial Fibrosis of the Lungs. *Bull. Johns Hopkins Hosp.,* 74:177, 1944.
9. Liebow, A. A., Steer, A., and Billingsley, J. G.; Desquamative Interstitial Pneumonia. *Amer. J. Med.,* 39:369, 1965.
10. Pratt, P. C.: Pulmonary Capillary Proliferation Induced by Oxygen Inhalation. *Amer. J. Path.,* 34:1033, 1958.
11. Roth, E. M.: *Space-Cabin Atmospheres. Part I—Oxygen Toxicity.* NASA SP-47, National Aeronautics and Space Administration, 1964.
12. Thomas, A. A.: Low Ambient Pressure Environments and Toxicity. *Arch Environ. Health,* 11: 316, 1965.
13. Weir, F. W., Bath, D. W., Yevich, P., and Oberst, F. W.: Study of Effects of Continuous Inhalation of High Concentrations of Oxygen at Ambient Pressure and Temperature. *Aerospace Med.,* 36:117, 1965.

Security Classification

DOCUMENT CONTROL DATA - R&D

(Security classification of title, body of abstract and indexing annotation must be entered when the overall report is classified)

1. ORIGINATING ACTIVITY *(Corporate author)*
Aerospace Medical Research Laboratories
Aerospace Medical Div., Air Force Systems Command
Wright-Patterson Air Force Base, Ohio 45433

2a. REPORT SECURITY CLASSIFICATION
UNCLASSIFIED

2b. GROUP
N/A

3. REPORT TITLE

PATHOLOGY OF OXYGEN TOXICITY IN FORTY MACACA MULATTA

4. DESCRIPTIVE NOTES *(Type of report and inclusive dates)*
Final Report - May 1965-April 1966

5. AUTHOR(S) *(Last name, first name, initial)*
Robinson, Farrel R., Major, USAF, VC
Harper, David T., Captain, USAF, MC
Kaplan, Harold P., Captain, USAF, MC
Thomas, Anthony A., MD

6. REPORT DATE
March 1967

7a. TOTAL NO. OF PAGES
16

7b. NO. OF REFS
13

8a. CONTRACT OR GRANT NO.

b. PROJECT NO. 6302

c. Task No. 630206

d.

9a. ORIGINATOR'S REPORT NUMBER(S)
AMRL-TR-66-234

9b. OTHER REPORT NO(S) *(Any other numbers that may be assigned this report)*

10. AVAILABILITY/LIMITATION NOTICES

Distribution of this document is unlimited.

11. SUPPLEMENTARY NOTES

12. SPONSORING MILITARY ACTIVITY
Aerospace Medical Research Laboratories,
Aerospace Medical Div., Air Force Systems
Command, Wright-Patterson AFB, O. 45433

13. ABSTRACT

Forty monkeys (Macaca mulatta) were exposed to 99-100% oxygen at pressures from 600 to 760 mm Hg. The acute exudative pulmonary response was seen in only three exposed at 760 mm Hg. The subacute proliferative pulmonary response was seen at all levels studied, the degree being directly related to time-dose exposures. In the high dose ranges clinical signs of illness were evident after 5-7 days exposure when the monkeys became listless and anoretic. By 14 days they were quite lethargic and had assumed a huddled position. Grossly, the heavy lungs had a gray, bloodless appearance. Microscopically, there was extreme proliferation of the interstitium and alveolar epithelium. None of the monkeys that were exposed at 600 mm Hg died, although mild focal proliferative changes were seen. After 31 days postexposure, these changes appeared as focal areas of atelectasis with mild septal fibrosis.

DD FORM 1 JAN 64 1473

Security Classification

Security Classification

14. KEY WORDS	LINK A ROLE	LINK A WT	LINK B ROLE	LINK B WT	LINK C ROLE	LINK C WT
Oxygen toxicity						
Macaca mulatta						
Lung pathology						
Proliferative lung lesions						
Clinical signs						
Mortality						
Recovery						

INSTRUCTIONS

1. ORIGINATING ACTIVITY: Enter the name and address of the contractor, subcontractor, grantee, Department of Defense activity or other organization *(corporate author)* issuing the report.

2a. REPORT SECURITY CLASSIFICATION: Enter the overall security classification of the report. Indicate whether "Restricted Data" is included. Marking is to be in accordance with appropriate security regulations.

2b. GROUP: Automatic downgrading is specified in DoD Directive 5200.10 and Armed Forces Industrial Manual. Enter the group number. Also, when applicable, show that optional markings have been used for Group 3 and Group 4 as authorized.

3. REPORT TITLE: Enter the complete report title in all capital letters. Titles in all cases should be unclassified. If a meaningful title cannot be selected without classification, show title classification in all capitals in parenthesis immediately following the title.

4. DESCRIPTIVE NOTES: If appropriate, enter the type of report, e.g., interim, progress, summary, annual, or final. Give the inclusive dates when a specific reporting period is covered.

5. AUTHOR(S): Enter the name(s) of author(s) as shown on or in the report. Enter last name, first name, middle initial. If military, show rank and branch of service. The name of the principal author is an absolute minimum requirement.

6. REPORT DATE: Enter the date of the report as day, month, year; or month, year. If more than one date appears on the report, use date of publication.

7a. TOTAL NUMBER OF PAGES: The total page count should follow normal pagination procedures, i.e., enter the number of pages containing information.

7b. NUMBER OF REFERENCES: Enter the total number of references cited in the report.

8a. CONTRACT OR GRANT NUMBER: If appropriate, enter the applicable number of the contract or grant under which the report was written.

8b, 8c, & 8d. PROJECT NUMBER: Enter the appropriate military department identification, such as project number, subproject number, system numbers, task number, etc.

9a. ORIGINATOR'S REPORT NUMBER(S): Enter the official report number by which the document will be identified and controlled by the originating activity. This number must be unique to this report.

9b. OTHER REPORT NUMBER(S): If the report has been assigned any other report numbers *(either by the originator or by the sponsor)*, also enter this number(s).

10. AVAILABILITY/LIMITATION NOTICES: Enter any limitations on further dissemination of the report, other than those imposed by security classification, using standard statements such as:

(1) "Qualified requesters may obtain copies of this report from DDC."

(2) "Foreign announcement and dissemination of this report by DDC is not authorized."

(3) "U. S. Government agencies may obtain copies of this report directly from DDC. Other qualified DDC users shall request through _____."

(4) "U. S. military agencies may obtain copies of this report directly from DDC. Other qualified users shall request through _____."

(5) "All distribution of this report is controlled. Qualified DDC users shall request through _____."

If the report has been furnished to the Office of Technical Services, Department of Commerce, for sale to the public, indicate this fact and enter the price, if known.

11. SUPPLEMENTARY NOTES: Use for additional explanatory notes.

12. SPONSORING MILITARY ACTIVITY: Enter the name of the departmental project office or laboratory sponsoring *(paying for)* the research and development. Include address.

13. ABSTRACT: Enter an abstract giving a brief and factual summary of the document indicative of the report, even though it may also appear elsewhere in the body of the technical report. If additional space is required, a continuation sheet shall be attached.

It is highly desirable that the abstract of classified reports be unclassified. Each paragraph of the abstract shall end with an indication of the military security classification of the information in the paragraph, represented as *(TS)*, *(S)*, *(C)*, or *(U)*.

There is no limitation on the length of the abstract. However, the suggested length is from 150 to 225 words.

14. KEY WORDS: Key words are technically meaningful terms or short phrases that characterize a report and may be used as index entries for cataloging the report. Key words must be selected so that no security classification is required. Identifiers, such as equipment model designation, trade name, military project code name, geographic location, may be used as key words but will be followed by an indication of technical context. The assignment of links, rules, and weights is optional.

Security Classification