U. S. NAVAL SUBMARINE MEDICAL CENTER

Submarine Base, Groton, Conn.

REPORT NUMBER 493

CEREBRAL AIR EMBOLISM

I. Basic Studies

by

Charles L. Waite, Walter F. Mazzone,
Michael E. Greenwood and Reynold T. Larsen

Bureau of Medicine and Surgery, Navy Department
Research Work Unit MR005.04-0055.09

Released by:

C. L. Waite, CAPT MC USN
COMMANDING OFFICER
U. S. Naval Submarine Medical Center

18 April 1967

DISTRIBUTION OF THIS DOCUMENT IS UNLIMITED

CEREBRAL AIR EMBOLISM I. BASIC STUDIES

by

Charles L. Waite,
Captain, MC, U. S. Navy,

Walter F. Mazzone,
Captain, MSC, U. S. Navy,

Michael E. Greenwood,

and

Reynold T. Larsen,
Lieutenant, MC, U. S. Navy

SUBMARINE MEDICAL RESEARCH LABORATORY

U. S. NAVAL SUBMARINE MEDICAL CENTER REPORT NO. 493

Bureau of Medicine and Surgery, Navy Department

Research Work Unit MR005.04-0055.09

Reviewed by:

Charles F. Gell, M.D., D.Sc.
Chief Scientist, SubMedResLab

Reviewed by:

Jack L. Kinsey, CAPT MC USN
Director, SubMedResLab

Approved and Released by:

Charles L. Waite
CAPT MC USN
COMMANDING OFFICER

SUMMARY PAGE

THE PROBLEM

To create an experimental model to study cerebral air embolism in live animals and to determine the role of compression and varying decompression on the outcome.

FINDINGS

A successful method of artificially producing and observing cerebral air embolism in live dogs was developed. The use of pressure to effectively treat this condition was reaffirmed and indications were found that prolonged decompression following compression to 165 feet is not necessary.

APPLICATIONS

Direct application of the experience and data collected is found in a possible modification to the current treatment of human cerebral air embolism as incurred by submarine personnel in escape training, SCUBA divers and aerospace personnel subjected to explosive decompression.

ADMINISTRATIVE INFORMATION

This investigation was conducted as a part of Bureau of Medicine and Surgery Work Unit MR005.04-0055—Pathological Physiology of Air Embolism and Decompression Sickness. The present report was approved for publication on 18 April 1967 and has been designated as Submarine Medical Center, Submarine Medical Research Laboratory Report No. 493,—this is Report No. 9 on the Work Unit listed above.

PUBLISHED BY THE NAVAL SUBMARINE MEDICAL CENTER

Distribution of this document is unlimited.

ABSTRACT

Using surgically created cranial windows and artificially producing cerebral air embolism by injecting air into the carotid arteries of live dogs, it was possible to observe the behavior and ultimate effect of cerebral intravascular air on a series of animals under varying modes of treatment and an untreated control group.

The results in the untreated controls were uniformly poor, whereas animals with cerebral air embolism who were treated with prompt recompression to 165 feet responded uniformly well. Only normal diving decompression was given and prolonged decompression, as in Navy treatment Tables III and IV, was not utilized. These results would indicate that the principle mode of therapy in air embolism should be rapid compression and **not** prolonged decompression.

CEREBRAL AIR EMBOLISM

I. BASIC STUDIES

INTRODUCTION

Traumatic cerebral air embolism is an acute, serious, occupational hazard associated with decompression and incurred by submarine personnel undergoing escape training, by individuals pursuing SCUBA diving as a vocation or hobby, and by aerospace pilots exposed to explosive decompression at ambient pressures of less than one atmosphere (1, 2, 3, 4). This condition should not be confused with decompression sickness (bends) which, though also related to decompression, has a somewhat different etiology and pathophysiology. In general, bends is less acute and tends in the average case to be of less serious import.

The designation 'traumatic' is proposed to differentiate this form of air embolism incurred in a diminishing ambient pressure from the 'accidental' variety occurring at one atmosphere in a hospital setting (5, 6, 7, 8, 9, 10).

The relationship of morbidity and mortality to the mode of escape training which has changed through the years is given in Figure 1, and can be seen to influence both traumatic and accidental types of embolism. Free ascent training is technically more difficult to master and has a resulting higher rate of occurrence of embolism than was found in older escape methods. The mastery of this technique by SCUBA divers is a necessity, if air embolism is to be avoided.

The incidence of dysbaric cerebral air embolism in relationship to submarine escape training at the Submarine Base New London, (Groton, Connecticut), in the past 35 years is given in Table I.

The National Safety Council estimated 60 deaths in 1965 were caused by SCUBA diving accidents, and a number of these were undoubtedly due to air embolism.

In the illness which is the subject of this series of experiments, the individual diver or submariner, is in a diminishing pressure situation which causes an expansion of gas in the pulmonary alveoli. If the normal exhalation route of the expanding alveolar gas is interrupted either voluntarily, as in breath-holding, or involuntarily, from trapped air, associated with pulmonary tract pathology, then the over-expansion and rupture of alveoli ensues. The gas is released into the pulmonary circulation and enters the cerebral circulation via the pulmonary vein, left heart, aorta and carotids. See Figure 2.

The pulmonary events, including the vital relationships of transpulmonary and transatrial pressures leading to alveolar rupture, have been well defined, (11, 12, 13, 14, 15, 16).

The wide clinical spectrum of symptoms and signs associated with cerebral air embolism include: Headache; vertigo; cranial nerve involvement; visual, auditory, and speech disturbances; loss of vital signs; and death.

Similarly, the coincident intrathoracic complications of pulmonary interstitial emphysema, mediastinal emphysema, and pneumothorax, have been studied and reviewed in several excellent papers, (12, 13). The cerebral events, however, have not been studied as closely, except in reports defining the clinical symptoms and signs and reviewing the experience with pressure therapy, (4, 17, 18, 19, 20).

Neither has the pressure treatment of cerebral air embolism been thoroughly evaluated or given the attention it deserves as the treatment of choice. Currently, there is little evidence, other than clinical, that speaks to the efficacy of six atmospheres

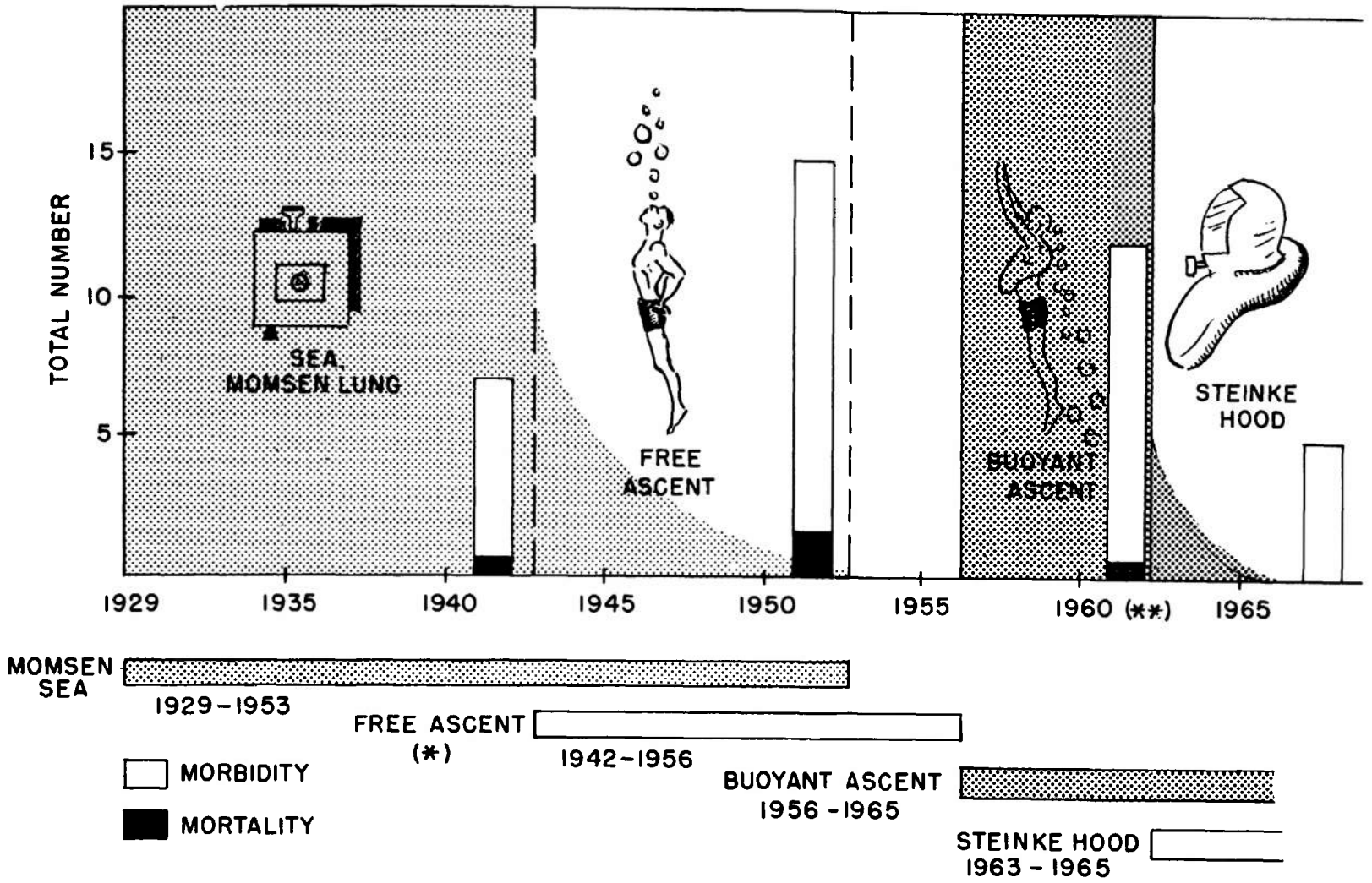

NOTE:

(*) FREE ASCENT IS STILL TAUGHT TO MEN UNDERGOING SCUBA TRAINING.

(**) ALL ASCENTS WERE MADE FROM 18', 50', AND 100' UNTIL 1961 AT WHICH TIME LADDER TRAINING AND 2 RUNS FROM 50' WERE SUBSTITUTED.

Figure 1. — Chronological Chart of Modes of Submarine Escape Training in the U. S. Navy.

YEARS	MODE	TOTAL NO. ESCAPES	TOTAL NO. AIR EMBOLISM (MORBIDITY)	DEATHS MORTALITY
1930-1953	S.E.A. MOMSEN LUNG	193,000	7	1
1942-1957	FREE ASCENT	17,583	15	2
1957-1965	BUOYANT ASCENT	130,679	12	1
1963-1965	STEINKE HOOD	32,679	5	0

Table I. — Morbidity and Mortality in Relation to Total Number of Simulated Escapes and Modes of Escape, U. S. Naval Submarine Escape Training Tank, New London, 1938-1963

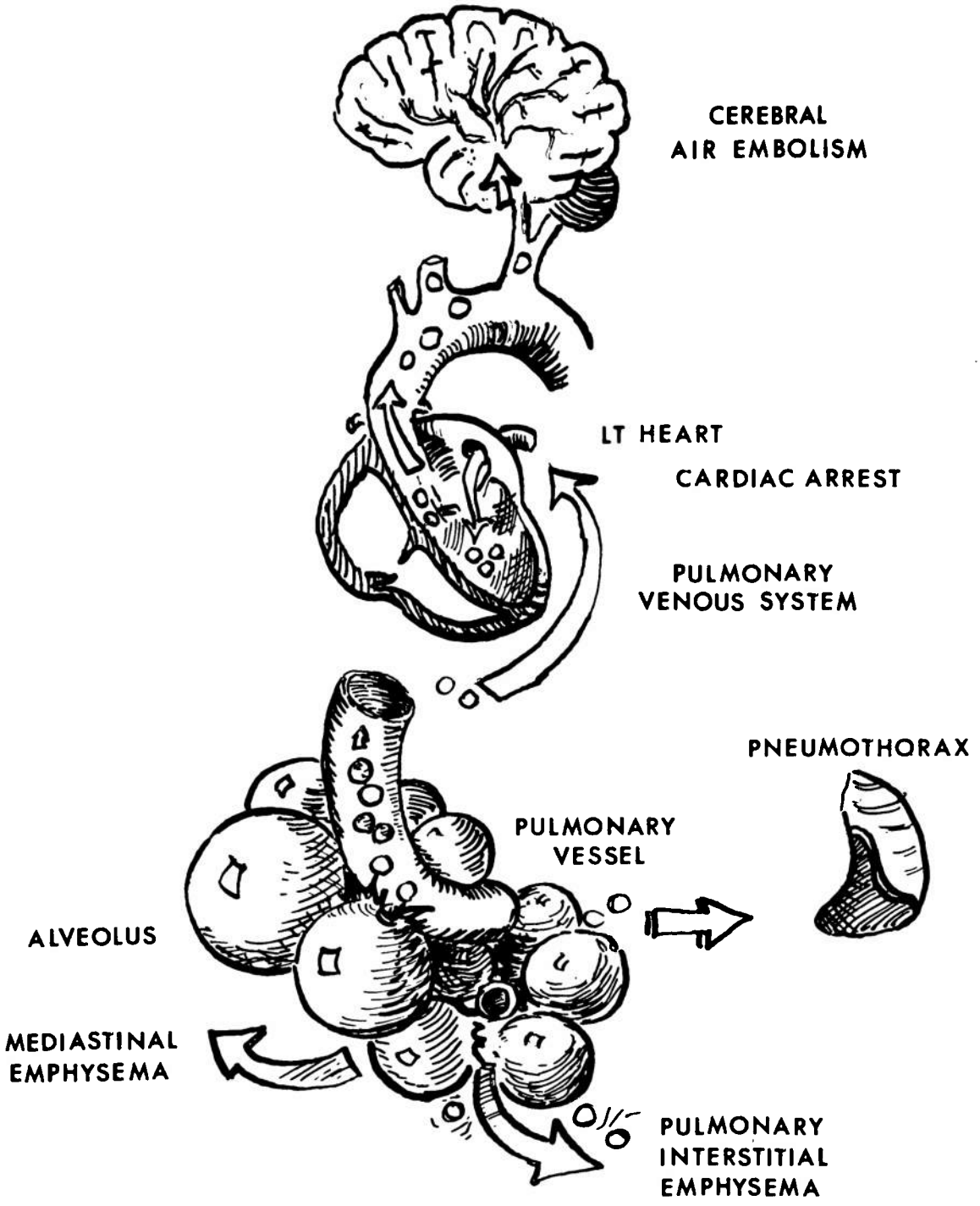

Figure 2. — Schematic of Potential Courses of Air from Ruptured Alveoli.

absolute of pressure as the optimum recompression required. At the same time, there is meager published evidence that pressures less than six atmospheres absolute are totally efficacious, (1, 2, 22).

Current thinking in the treatment of pressure illnesses tends towards less prolonged exposure of damaged tissues to high partial pressures of inert gas (24). This principle may also be applicable to the treatment of air embolism.

The occasional so-called "recurrence" of cerebral air embolism during the pressure treatment phase is a doubtful circumstance, more likely due to post-embolic cerebral damage, edema, and increased intracranial pressure.

The series of experiments to be described is directed toward a better understanding of the cerebral events of air embolism and the effects of recompression in the natural history of the injury, —all with a view toward developing a more effective treatment.

PURPOSE OF THE STUDY

The purposes of this study are listed below:

(1) To develop a technique to produce and observe cerebral air embolism in vivo in mammals with a high degree of consistency;

(2) To observe grossly the effect of cerebral intravascular bubbles on the cerebral circulation and the tissues supplied by the cerebral circulation;

(3) To observe in vivo the life history of cerebral intravascular air and its residual effect on the untreated embolized animal;

(4) To observe in vivo the life history of cerebral intravascular air and its effect on cerebral tissue using immediate recompression to 165 feet (six atmospheres absolute) as the mode of treatment.

(5) To observe in vivo the cerebral cortex and cerebral blood vessels of embolized animals during the decompression phase, utilizing standard 170-foot/10 minute diving table. This is in lieu of the U. S. Navy Standard Treatment Tables III and IV. In this phase, particular attention will be paid to possible reappearance or recurrence of the cerebral intravascular air.

MATERIALS AND METHODS

Initial cerebral studies in vivo were done on prepared cats and small dogs, injecting air into the carotid and observing cerebral intravascular bubbles in the region of the frontal cortex. From these studies it was determined that dogs weighing 25-40 pounds were the most satisfactory species for these experiments.

Additionally, a cranial window technique was adopted to visualize the cortex. This was done using a modification of Pudenz and Shelden's lucite calvarium technique, (21). All subsequent animals used were mongrel dogs which were prepared with a unilateral cranial window 2.5 cm in diameter in the parieto-occipital area, except one dog which was prepared with bilateral cranial windows. These windows were created seven days prior to any experimentation in order to allow the animal to stabilize after the procedure. After four experimental runs with the cranial window, the visualization technique was changed to a simple craniotomy for all succeeding runs. See Figure 3.

Twenty-four hours prior to an experiment, the carotid artery on the same side as the window was dissected free and isolated through a cervical incision and sterile tape was looped around it. The tape was allowed to protrude through a partially closed incision and gave ready access to the carotid when embolization was desired.

Ambient air in the amount of 1-7 cc was injected into the carotid with an ordinary disposable syringe and 18 gauge needle to artificially produce the cerebral air embolism.

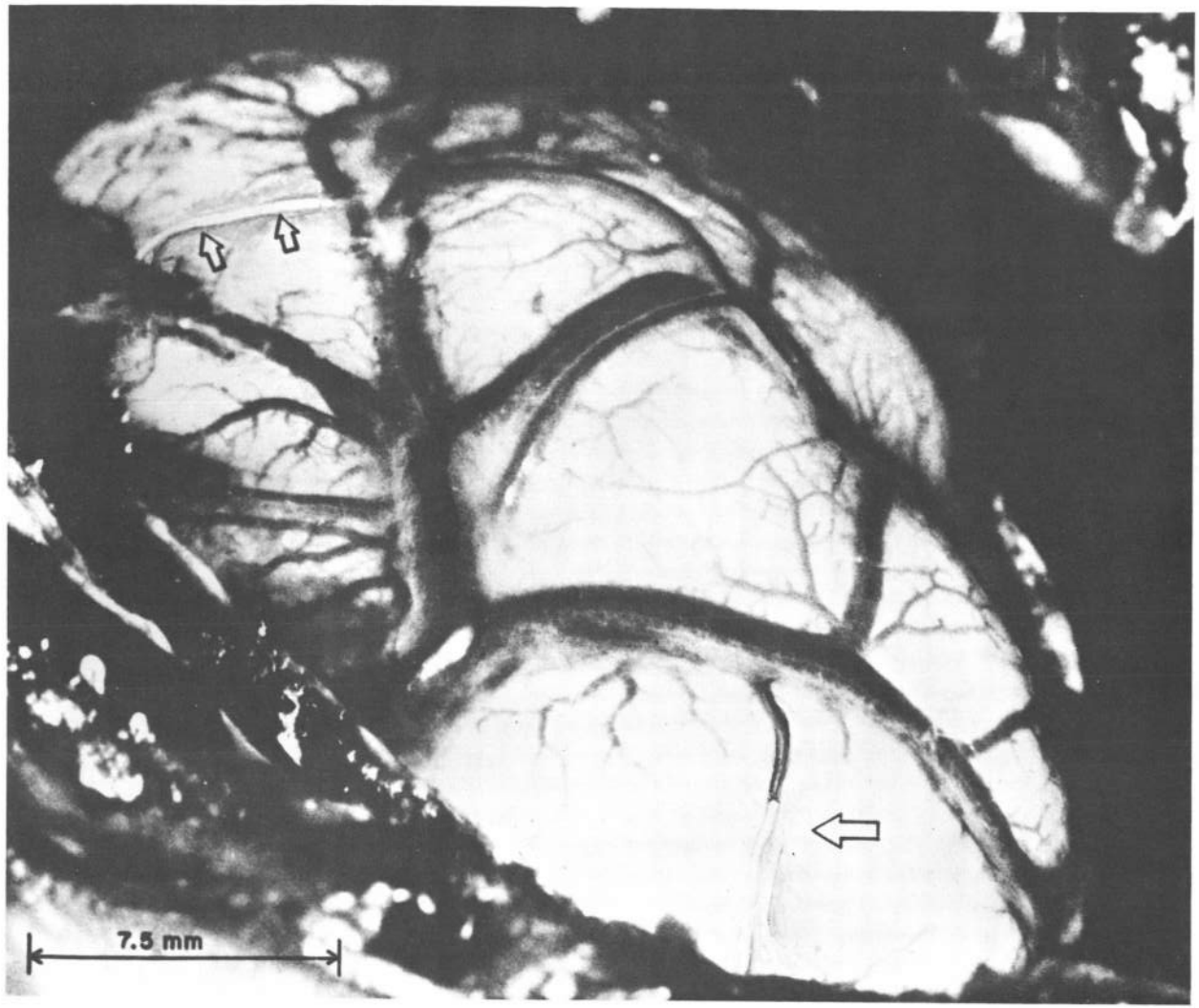

Figure 3. — Cranial Window (X3.3) as seen Through the Dissecting Microscope,—Note Air Filled Arteries as Indicated by Arrows.

Recording of Results:

Four modes were utilized to record the experiments. They were:

(1) Direct observation and tape recording;

(2) Six-frame-per-second photography, —color, and black and white.

(3) Color motion-pictures, —sound and silent;

(4) Closed circuit TV.

Types of Experimental Runs:

The types of runs with the embolized animals were varied to meet the objectives of the study. Initial experimental runs were concerned only with the production of a satisfactory cerebral air embolism, permitting observation of intravascular bubbles and their effect on the circulatory dynamics and the cerebral tissue supplied. In this series, five dogs in six separate runs were observed. All runs were done on the surface at 14. 7 p.s.i. (one atmosphere).

In the second series, three dogs were embolized at one atmosphere and taken to treatment depth, then returned to surface on a standard 170-foot diving decompression table for the appropriate time on the bottom. These are hereafter referred to as "bounce dives."

In another series, three dogs were embolized at 33 feet (two atmospheres), brought to the surface and then given bounce dive treatment to 165 feet. This was done to simulate the occurrence of cerebral air embolism in a decreasing ambient pressure environment, much as it occurs in the true situation. When dogs were embolized without treatment, the experiments were conducted in the veterinary operating suite. When the dogs were embolized and treated with pressure, the entire procedure was conducted in the large recompression chamber at the Submarine Medical Research Laboratory. This permitted room for observers, motion-picture cameras, TV monitors and monitoring equipment. See Figure 4.

RESULTS AND OBSERVATIONS

A total of 14 embolism experiments were conducted (see Table II). Three were unsuccessful, in that attempts to induce artificial cerebral air embolism via the carotid route could not be accomplished. This was invariably due to thrombosis of carotid vessel incurred during the preparation.

Five dogs were embolized and not given treatment with recompression; two expired within twenty minutes, and three survived, but with severe residual damage evident. The residual damage was evidenced by alterations in the state of consciousness, major paralysis, ataxia, incoordination, convulsions, muscle spasm, reflex changes, anorexia, and cranial nerve damage.

Of the six successfully embolized at one and two atmospheres, and then treated with recompression to 165 feet, five survived without demonstrable residual damage. One dog (#12) survived, but with severe residuals in evidence, of the type already described. On examination of the film record, (which took several weeks to process), a rupture of a cerebral vasculature was noted. Not only were the air bubbles expelled as a froth over the brain surface, but with restoration of the circulation by recompression, gross cerebral hemorrhage ensued. At autopsy, gross section of this animal's brain (see Figure 5) revealed a massive deep hemorrhage in the region of the area observed and reaffirmed by the motion-picture record.

Observations Concerning the Cerebral Intravascular Air:

With the cerebral window exposures performed, the observations for the most part were made on the anterior cerebellar and posterior cerebral branches of the posterior communicating artery of the carotid. The arterial vessels under observation with the dissecting microscope and motion-picture camera had diameters of from 30 microns to 2 mm.



Figure 4. — Interior of Large Pressure Chamber Showing Experimental and Photographic Set-Up for Embolism Studies.

TABLE #2 SUMMARY OF OBSERVATIONS

Date	Animal	Type of Run	Amt. of Air Inj. Carotid	Cerebral intra-vascular bubbles observed	Treatment	Outcome & Remarks
10-23-64	Dog #1	Frontal lobe observation 1 atmosph.	5 cc	Yes	None	Circul. blocked - death in 18 min.
12-7-64	Dog #2	Temporal - cranial window - embolized at 1 atmosphere	2 cc	Yes	165 ft. bounce dive / 170 ft. dive table	Cerebral intravascular bubbles disappeared 80-100'- dog survived
12-10-64	Dog #2	Temporal - cranial window - embolized at 33 ft.(2 atmosph.)	1 cc	Yes	None	Dog expired - 12 min. Circul.effect.blocked
1-15-65	Dog #3	Occipito-Parietal window / 1 atmosphere	Repeated attempts to embolize unsuccessful	No	None	Unsuccessful / Thrombosed Carotid
1-21-65	Dog #3	Occipito-Parietal window / Embolized at 33 ft. (2 atmosph.)	1 cc	Yes	Surfaced - then 165 ft.bounce dive / 170 ft.dive table	Very poor on surface - survived - no residuals bubbles gone at 100 ft.
1-30-65	Dog #4	Bilateral Occipito-Parietal windows	Repeated attempts to inject air unsuccessful	No	None	Unsuccessful / Thrombosed vessels - Dog survived
2-5-65	Dog #5	Bilateral Occipito-Parietal Embolized at 1 atmosph.	5 cc	Yes	165 ft.bounce / 170 ft.dive table	Cerebral intravascular bubbles gone at 100 ft.
5-27-65	Dog #6	Lt. craniotomy Embolized at 1 atmosph.	5 cc	Yes	None	Proved bilateral widespread distribution of air from unilateral carotid injection - dog sacrificed
6-15-65	Dog #7	Lt. craniotomy Embolized at 1 atmosphere	5 cc	Yes	165 ft. bounce dive / 170 ft. dive table	TV camera run successful - dog survived / Bubbles no longer observed after 60 ft.
12-15-65	Dog #8	Lt. craniotomy Embolized at 1 atmosphere	Repeated attempts to embolize unsuccessful	No	None	Unsuccessful run - thrombosed vessels
12-15-65	Dog #9	Lt. craniotomy Embolized at 1 atmosphere	7 cc	Yes	None	Dog survived with serious residuals - sacrificed at 20 days - post-embolism / Autopsy
1-17-66	Dog #10	Lt. craniotomy Embolized at 1 atmosphere	7 cc	Yes	165 ft. bounce dive	Dog survived - no residuals
1-17-66	Dog #11	Skull intact	5 cc	No	None	Survived with residuals
1-18-66	Dog #12	Lt. craniotomy 2 atmospheres	7 cc at 33 ft.	Yes	165 ft. bounce dive	Survived but with severe residuals - dog sacrificed / Film record shows severe cerebral hemorrhage coincident with bubble insult. No intravascular bubbles after 80 ft. / Autopsy

Table II. — Results of Fourteen Animal Embolism Experiments.

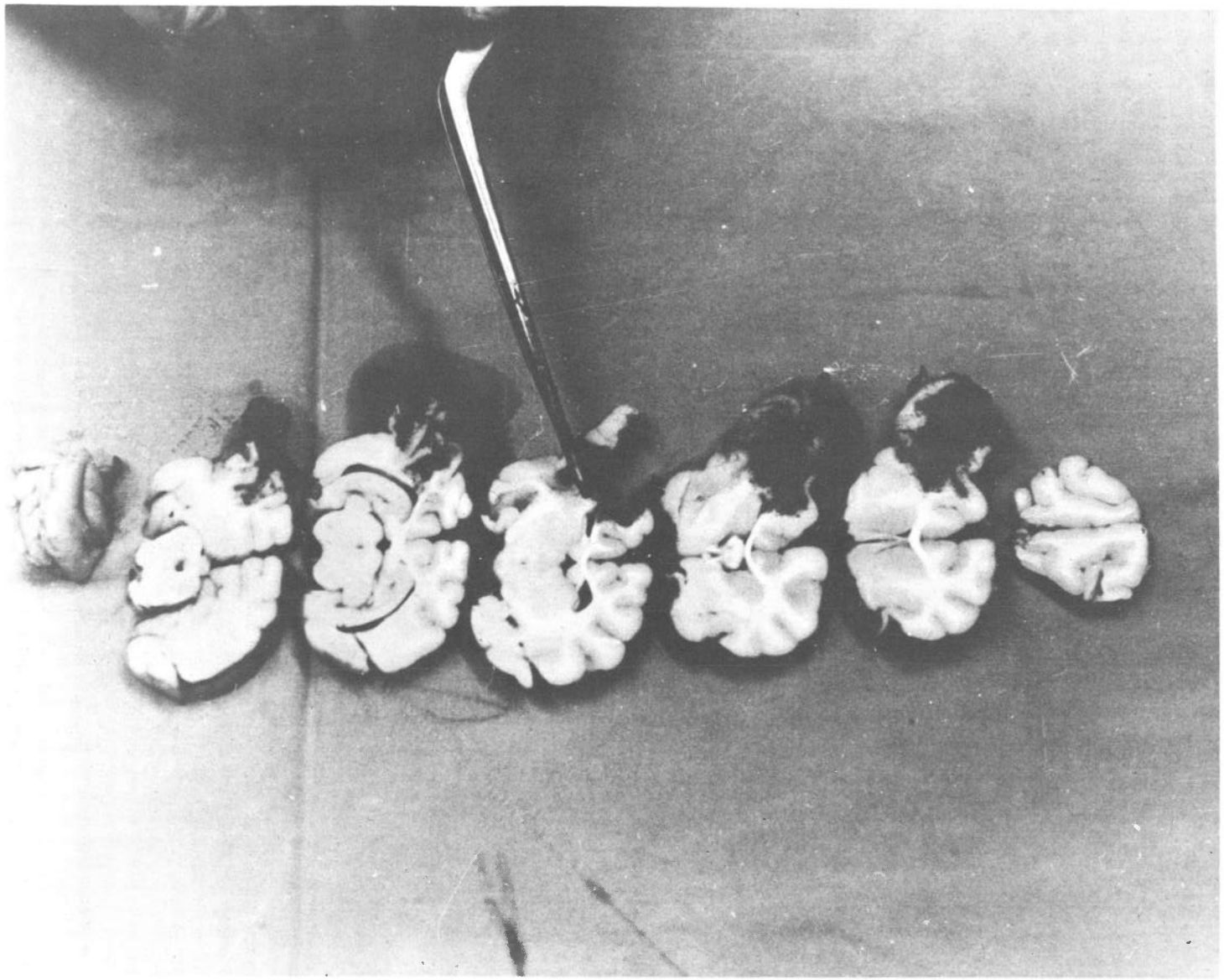

Figure 5. — Cerebral Sections Showing Gross Hemorrhage Which Occurred Coincident With Run No. 14 (Dog No. 12).

Typically, the bubbles conformed to the size and shape of the blood vessels. The majority of the air passed through the larger arteries very rapidly, but on reaching the branches of these arteries came to rest in a way that effectively blocked arterial circulation. In some instances, entire branches were filled with air; in others, the air bubbles were lined up in a row with small amounts of blood separating them with thin biconcave menisci. The very small arteriolar vessels were completely filled with air and appeared as a very thin, silvery network on the cortical surface. The largest arteries observed to be blocked by the bubbles were 2. mm in diameter. However, most of the vessels observed which were filled with air and showed evidence of circulatory obstruction were smaller than 2 mm, and were in the range of 30-60 microns. This confirmed the observations of Curtillet and Curtillet (23), who, doing similar work on dogs in 1939-40, reported effective blockage in arterioles of 30-40 microns in diameter.

At the blood/air interfaces, the circulation was at a standstill, and the pulsations of the heart could be seen. In other small arteries there was a slow pulsating progression of the bubbles in response to the systolic pressure peaks. In the series of photographs (Figure 6) a progression of such a bubble can be seen. The pulsating nature of the progression can be seen by the small amount of blood pushed into a branch and then left behind by the recession of the pulse (Figure 6-C).

The surrounding brain tissue exposed by the cranial windows came under observation and typically showed a pallor which in the untreated cases gave way to a reactive hyperemia. Minor flare hemorrhages and petechial air embolism were also noted. Moderate edema was evident in some cases after an hour or more.

In the six dogs embolized and then recompressed to 165 feet, the following results were observed: Two showed that all the bubbles observed grossly had vanished by 100 feet (four atmospheres); three showed the same results by 80 feet; and one dog, by 60 feet.

In every instance there was evidence of a change in bubble size and partial restoration of the circulation just beyond 33 feet. In none of the experiments were intravascular bubbles seen to persist after pressure equivalent to four atmospheres was reached.

Equally important, in no instance was there a reappearance of bubbles during or after decompression, using a Standard Navy Decompression Table for 170 feet (10 min.) at a standard ascent rate of 25 feet per minute.

There was no attempt in this series to treat cerebral air embolism with pressures less than six atmospheres absolute, even though there is some indication that this maximum need not be applied.

A future series is planned, using four atmospheres and the no-recompression control series.

COMMENTS AND CONCLUSIONS

In the past, the civilian medical community has not given the pressure therapy of cerebral air embolism the recognition it deserves as the treatment of choice. This was undoubtedly due to the general non-availability of such facilities in the average hospital setting. Today, however, the current interest in hyperbaric medicine has resulted in the establishment and maintenance of pressure facilities in many leading medical centers throughout the country. Personnel responsible for these facilities should develop an awareness, and indeed the technical competence, to treat decompression sickness and air embolism. With this capability, the facility can be used to treat not only the occasional air embolism seen in clinical medicine, but the increasing number of civilian SCUBA diving accidents as well.

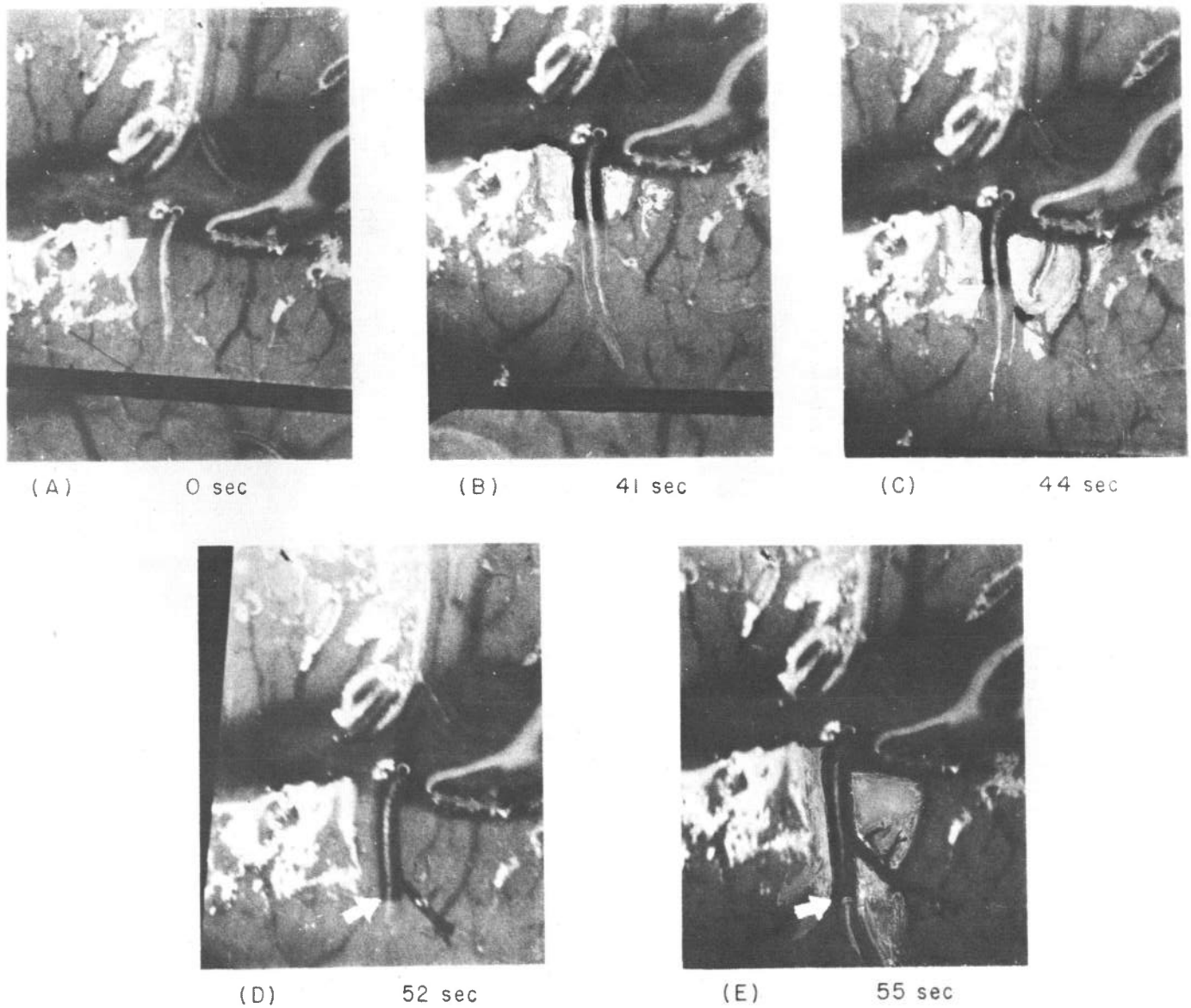

Figure 6. — Cerebral Artery (1 mm. in diameter), Showing Progress of Circulation Against Untreated Air Embolism (6 fr/sec). Indication of pulsation can be seen in 6C.

The present study, while limited in scope and design, did accomplish the following:

(1) A technique for observing and photographing intravascular cerebral air embolism in vivo was developed and refined;

(2) In a controlled series, the efficacy of pressure as a means of relieving the circulatory obstruction caused by air embolism was observed and reaffirmed;

(3) There were indications of the pressures necessary to relieve the air embolism. Maximum effects of recompression were observed between 33 feet (two atmospheres absolute) and 100 feet (four atmospheres absolute). Until further experiments are performed, however, there is sufficient evidence to permit one to say that the maximum pressure of 165 feet (six atmospheres absolute) should be considered as unnecessary;

(4) Additionally, there was good indication that prolonged recompression, as in Tables III and IV of the U. S. Navy Standard Treatment Tables, is not necessary to effectively treat cerebral air embolism. All of the successful pressure treatment runs in this series consisted of bounce dives to 165 feet for less than ten minutes and return to the surface at 25 feet per minute with a two-minute stop at ten feet (170 ft. Table);

(5) The role of post-embolic edema could not be measured or evaluated because of the unrealistic presence of the cranial window which undoubtedly modified this reaction;

(6) Ideas for additional studies were developed.

In future studies in this series, it is planned to:

(1) Evaluate the effect of treatment using pressures less than six atmospheres absolute;

(2) Evaluate the effects of hyperbaric oxygen at 60 and 30 feet, added to the pressure treatment regimen.

SUMMARY

The medical aspects and pathophysiology of cranial air embolism are briefly reviewed. The term "dysbaric cerebral air embolism" is proposed to differentiate this condition, incurred in a diminishing ambient pressure, from the "accidental" type seen in the hospital setting at the constant pressure of one atmosphere.

A method of artificially inducing cerebral air embolism and observing and photographing the intravascular cerebral air in living dogs is described.

Observations on the life history and behavior of cerebral arterial air at one atmosphere absolute (14.7 p.s.i.) and the effect of pressure therapy to six atmospheres absolute (88 p.s.i.) and subsequent decompression to one atmosphere are presented.

The use of pressure in effectively treating cerebral air embolism is reaffirmed, and there is indication that a prolonged decompression following recompression to 165 feet is not necessary.

The present study confirms that six atmospheres absolute is effective in grossly relieving cerebral air embolism. Effective treatment with pressures less than six atmospheres awaits further study.

Additional studies are proposed.

NOTE: A film, entitled "Cerebral Air Embolism" (12-min. color-sound) was made at the Naval Submarine Center, which shows some of the experiments conducted and described in this paper.

The cranial window and carotid artery preparation of the dogs are shown. Two typical air embolism experiments are depicted with closeups of the embolism and its effect on cerebral vasculature and tissue in living dogs. The first is an untreated case at one atmosphere, and the second a treated case using pressure to 165 feet. The effect of pressure in relieving the air embolism is seen. The clinical neurological effects after embolization are shown and compared for both cases.

A special case is shown in which the rupture of a cerebral vessel is seen to occur coincident to the insult of air embolism. (Film is unnumbered; but three copies are available on loan from Commanding Officer, Submarine Medical Center, Box 600 —Naval Submarine Base, Groton, Connecticut 06340).

REFERENCES

1. Brown, E. W., Shock due to excessive distention of the lungs during training with escape apparatus. U. S. NavMedBull 29: 366-370, 1931
2. Adams, B. H., Observations on submarine lung training. U.S. NavMedBull 29: 370-372, 1931
3. Polak, B. and B. H. Adams, Traumatic air embolism in submarine escape training. U.S. NavMedBull 30: 165, 1932
4. Kinsey, J. L., Air embolism as a result of submarine escape training. U. S. Armed Forces Med. J. 5: 243, 1956
5. Heuer, G. J., W. D. Andrus and A. Taylor, in Surgery of the Thorax, Nelson's Loose Leaf Surgery, Prior, Hagerstown 4:5, 387-588, 1941
6. Besnier, E., Notes on the cause of death following a thoracentesis, Bull. Soc. Med. Hosp, Paris, 12:24-32, 1876
7. Kelly, H. G., W. C. Gibson and J. F. Meakins, Cerebral air embolism following artificial pneumothorax, Canad. Med. Assn. J. 56:388-91, 1947
8. Durant, T. M., Cardiovascular accidents due to gas embolism, Trans. Amer. Climat. Assn. 60: 87-98, 1948
9. Baker, D. V., Jr., R. Warren, J. Homans and D. Littman, Pulmonary Embolism, New Eng. J. Med. 24:923-928, 1950
10. Stallworth, J. M., J. B. Martin and R. W. Postlethwait, Aspiration of the heart in air embolism, J.A.M.A. 143: 1250-1251, 1950
11. Adams, B. H. and I. B. Polak, Traumatic lung lesions produced in dogs by simulating submarine escape, U.S. NavMedBull 31: 18-20, 1931
12. Durant, T. M. and M. J. Oppenheimer, Embolism due to air and other gases, Vet. Admin. Bulletin. MB-1, July 1957
13. Macklin, M. J. and C. C. Macklin, Malignant interstitial emphysema as an important occult complication in many respiratory diseases and other conditions, Medicine 23:4, 1944
14. Griffin, R. J., Intrapulmonary gas pressures in arterial air embolism, Ann. Int. Med. 17:295, 1942
15. Liebow, A. A., J. E. Stark, J. Vogel and K. E. Schaefer, Intrapulmonary air trapping in submarine escape training casualties. U. S. Armed F. Med. J. 10:265, 1959
16. Schaefer, K. E., W. P. McNulty, Jr., C R. Carey and A. Liebow, Mechanisms in the development of interstitial emphysema and air embolism in decompression from depth J. Appl. Physiol. 13:15-29, 1958
17. Peirano, J. H., H. J. Alvis and G. J. Duffner, Submarine Escape Training Experience. 1929-1954. U.S. NavMedResLab Report 264 XIV:4, 1955
18. Moses, H. Casualties in individual submarine escape, U.S.N. SubMedCen Report 438, 1964
19. British Submarine Escape Mission, Report of Submarine Escape Committee, Appendix I, 1946
20. Hoff, E. C. and L. J. Greenbaum, Jr. A Bibliographical Sourcebook of Compressed Air, Diving and Submarine Medicine. Vol. II. ONR/BuMed, 1954
21. Pudenz, R. H. and C. H. Shelden, The lucite calvarium, a method for direct observation of the brain. J. Neurosurg. 3:487-505, 1946
22. Behnke, A. R., Analysis of accidents occurring in training with the submarine "lung." Nav MedBull 30 177-185, 1932
23. Curtillet, E. and A. Curtillet, Etude experimentale de l'embolie gazeuse. J. Physiol. Path. Gen. 40:573-584, 1939-40 (Abstr.)
24. Goodman, M. W. and Workman, R. D. Minimal recompression oxygen breathing approach to treatment of decompression sickness in divers and aviators. USN Exp. Diving Unit Research Report 5-65 of 15 Nov 1965